



Involvement of *Helicobacter Pylori* in Ocular Adnexa Lymphoma

Antonio Travaglino¹ · Mirella Pace¹ · Silvia Varricchio¹ · Daniela Russo¹ · Novella Pugliese² · Alessandro Severino² · Marco Picardi² · Fabrizio Pane² · Luigi Insabato¹ · Stefania Staibano¹ · Massimo Mascolo¹ 

Received: 3 July 2019 / Accepted: 11 June 2020 / Published online: 18 June 2020
© Arányi Lajos Foundation 2020

Abstract

Helicobacter pylori has been proposed as a possible etiologic factor of ocular adnexa lymphoma (OAL), although with conflicting results. To assess the involvement of *H. pylori* in OAL, as (1) *H. pylori* DNA positivity on OAL specimens, and (2) prevalence of *H. pylori* gastric infection in patients with OAL. A systematic review of studies assessing *H. pylori* in patients with OAL was conducted by searching electronic databases from their inception to May 2019. Pooled positivity for *H. pylori* in OAL specimens detected by polymerase chain reaction, and pooled prevalence of *H. pylori* gastric infection, were calculated with 95% confidence interval (CI). Eleven studies with 308 patients were included. Pooled positivity for *H. pylori* was 16.8% in all OALs and 22.7% in MALT OAL, with high heterogeneity among studies. Pooled prevalence of *H. pylori* gastric infection in patients with OAL was 34.7%, with low statistical heterogeneity. In conclusion, *H. pylori* seems to be involved in a subset of OAL, but the heterogeneity found needs to be investigated in further studies. The prevalence of *H. pylori* gastric infection in patients with OAL does not seem to differ from that of the general population.

Keywords Orbit · Ocular adnexa · Lymphoma · *Helicobacter pylori* · Antibiotic · Extranodal

Introduction

Ocular adnexal lymphoma (OAL) accounts for 5–15% of all extranodal lymphomas. In 60–80% of cases, OAL is a mucosa associated lymphoid tissue (MALT) lymphoma [1–3].

Several possible etiopathogenetic factors have been hypothesized for OAL, with a particular emphasis for chronic infections [1–4]. The main infectious agents studied have been bacteria of the *Chlamydia* genus (in particular *C. psittaci*), hepatitis viruses and *Helicobacter pylori* [4–15]. The importance of the identification of an etiologic infectious agent lies in the possibility of using targeted antibiotic therapies to eradicate the lymphoma [7, 8, 15–17]. The best example in this

field is gastric MALT lymphoma, in which antibiotics against *H. pylori* are considered as the first-line treatment [18].

In this review, we focused on the involvement of *H. pylori* in OALs. Given the contrasting results about a possible etiopathogenetic role of *H. pylori* in OAL [5–15], we aimed to define whether such role can reasonably be hypothesized. For this purpose, we planned a systematic review and meta-analysis to quantify both the presence of *H. pylori* in OAL specimens and the prevalence of *H. pylori* in patients with OAL.

Materials and Methods

For this review, methods were elaborated on the basis of our previous studies [19–21]. Each review stage was performed independently by three authors (AT, MP and MM); all authors consulted in the case of disagreement. This review was reported according to the PRISMA statement [22].

Electronic supplementary material The online version of this article (<https://doi.org/10.1007/s12253-020-00848-6>) contains supplementary material, which is available to authorized users.

✉ Massimo Mascolo
mmascol@gmail.com

¹ Department of Advanced Biomedical Sciences, Pathology Section, Anatomic Pathology Unit, University of Naples “Federico II”, Via Sergio Pansini, 5, 80131 Naples, Italy

² Department of Clinical Medicine and Surgery, Hematology Section, University of Naples “Federico II”, Naples, Italy

Search Strategy and Study Selection

Six electronic databases (Scopus, Web of Sciences, MEDLINE, OVID, the Cochrane library and Google

Table 1 Characteristics of the included studies

Study	Country	Period of enrollment	Sample size	Location	MALT-type	Method for <i>H. pylori</i> detection	
						H. Pylori in OAL	H. Pylori Gastritis
2004 Chan	USA	1999–2002	6	5 conjunctiva, 1 orbit	5/6	PCR urease B, vacA	serology, histology, culture
2006 Chan	Multicenter	1996–2003	7	3 orbit, 2 eyelid, 2 more than one site	7/7	PCR urease B	serology
2006 Ferreri	Italy	1990–2004	31	12 conjunctiva, 19 orbit or lacrimal gland	31/31	not assessed	histology
2006 Gruenberger	Austria	unclear	11	4 orbit, 3 conjunctiva, 3 lacrimal gland, 1 more than one site	11/11	not assessed	histology, breath test, serology
2007 Goebel	Germany	1985–2005	40	unclear	22/40	PCR vacA	not assessed
2007 Sjo	Denmark	unclear	13	conjunctiva	13/13	IHC, PCR 16S rDNA	not assessed
2008 Gruenberger	Austria	2000–2006	45	24 orbit, 11 lacrimal, 7 conjunctiva, 3 more than one site	45/45	not assessed	histology, breath test, serology
2008 Lee	Korea	2002–2006	15	conjunctiva	15/15	PCR 16S rDNA, vacA	not assessed
2010 Decaudin	France	1970–2007	51	36 conjunctiva, 32 orbit, 10 lacrimal gland, 4 eyelid	41/51	PCR 16S rRNA	histology, PCR 16S rRNA
2012 Cai	China	2008–2009	14	conjunctiva	14/14	PCR 16S rRNA	not assessed
2012 Ferreri	Multicenter	2006–2010	47	23 conjunctiva, 14 orbit, 5 lacrimal gland, 5 more than one site	47/47	not assessed	serology, breath test

OAL ocular adnexa lymphoma, IHC immunohistochemistry, PCR polymerase chain reaction

Scholar) were searched from the inception of each database to May 2019. Several different combinations of the following text words were used: lymphoma, ocular adnexa*, orbit, conjunctiva, eyelid, Helicobacter, *H. pylori*. All studies assessing the presence *H. pylori* in OAL tissue specimens, or the presence of *H. pylori* gastric infection in patients with OAL, were included. Exclusion criteria, defined a priori, were: case reports, reviews, data not extractable.

Data Extraction

Original data were extracted without modifications. Main extracted data were the total number of patients with OAL, the number of patients with *H. pylori*-positive OAL specimens, and the number of patients with both OAL and *H. pylori* gastric infection. Secondary data extracted were country, period of enrollment, methods for *H. pylori* detection in OAL specimens, methods for *H. pylori* gastric infection detection.

Risk of Bias within Studies Assessment

The risk of bias within studies was assessed by using the QUADAS-2 [23]. The four domains assessed in each study were: 1) “Patient selection” (i.e. if patients were selected consecutively, or if at least inclusion criteria and period of enrollment

were reported.); 2) “Index test” (i.e. if methods for *H. pylori* detection were clearly described); 3) “Reference standard” (i.e. if histological slides of OALs were reviewed to confirm the diagnosis); 4) “Flow” (i.e. if all OALs were assessed for the presence of *H. pylori*). For each domain, and in each study, the risk of bias was categorized as “low”, “high” or “unclear”, as previously described [24–26]. The risk of bias in the domains 2 and 4 was assessed separately for the two outcomes of our review (positivity for *H. pylori* in OAL tissue specimens and prevalence of *H. pylori* gastric infection in patients with OAL).

Data Analysis

The positivity rate of *H. pylori* in OAL tissue specimens was calculated as the number of *H. pylori*-positive OAL by the total number of OALs assessed. The prevalence of *H. pylori* gastric infection in patients with OAL was calculated as the number of patients with OAL and *H. pylori* gastric infection by the total number of patients with OAL assessed. Both values were calculated for each study and as pooled estimates and reported graphically on forest plots, with 95% confidence interval (CI). The random effect model of DerSimonian-Laird was used to pool data.

As previously described [27–29], statistical heterogeneity was categorized by using Higgin’s inconsistency index (I^2) as

follows: null ($I^2 = 0\%$), minimal ($0 < I^2 \leq 25\%$), low ($25\% < I^2 \leq 50\%$), moderate ($50\% < I^2 \leq 75\%$) or high ($I^2 > 75\%$).

Data analyses were performed by using Review Manager 5.3 (Copenhagen: The Nordic Cochrane Centre, Cochrane Collaboration, 2014) and Comprehensive Meta-Analysis (Biostat, 14 North Dean Street, Englewood, NJ 07631, USA).

Results

Study Selection and Characteristics

Eleven studies were finally included, with a total of 308 patients with OAL, out of which 279 (90.6%) were MALT-type

	Risk of Bias					
	Patient Selection	Index Test*	Index Test**	Reference Standard	Flow*	Flow**
2004 Chan	+	+	+	+	+	-
2006 Chan	?	+	?	+	+	?
2006 Ferreri	+		+	+		+
2006 Gruenberger	?		?	+		+
2007 Goebel	+	+		?	+	
2007 Sjo	?	+		+	+	
2008 Gruenberger	+		?	+		?
2008 Lee	+	+		?	+	
2010 Decaudin	+	+	+	+	-	+
2012 Cai	+	+		?	+	
2012 Ferreri	+		+	+		+

- High
 ? Unclear
 + Low

Fig. 1 Assessment of risk of bias. Summary of risk of bias for each study; Plus sign: low risk of bias; minus sign: high risk of bias; question mark: unclear risk of bias; grey boxes: not appropriate; *: domain related to the assessment of *H. pylori* in ocular adnexa lymphoma tissue specimens; **: domain related to the assessment of *H. pylori* gastric infection

[5–15]. The process of study selection is reported in Supplementary Fig. 1.

Positivity for *H. pylori* in OAL tissue specimens was assessed in 7 studies [5, 6, 9, 10, 12–14], by using polymerase chain reaction (PCR) with primers for *urease B* gene [5, 6], *vacA* gene [5, 9, 12], 16S rDNA [10, 12], or 16S rRNA [13, 14]. The presence of *H. pylori* gastric infection was assessed in 7 studies [5–8, 11, 13, 15], by using serologic analyses [5, 6, 8, 11, 15], urea breath test [8, 11, 15], cultural analyses [5], histologic examination [5, 7, 8, 11, 13] or PCR [13].

Characteristics of the included studies are reported in Table 1.

Risk of Bias Assessment

For the “patient selection” domain, the risk of bias was considered low for 8 studies (it was clearly stated that patients were consecutive [11–13, 15], or at least inclusion criteria and period of enrollment were reported [5, 7, 9, 14]), and unclear for 3 studies [6, 8, 10].

For the “index test” domain, with regard to the assessment of *H. pylori* on OAL tissue specimens, the risk of bias was considered low for all studies (methods for *H. pylori* detection clearly reported). With regard to the assessment of *H. pylori* gastric infection, the risk of bias was considered low for 4 studies (methods clearly reported [5,7,13,15]) and unclear for 3 studies (it was not clear if each patient was assessed with all methods [6, 8, 11]).

For the “reference standard” domain, the risk of bias was considered low for 8 studies (histological slides reviewed to confirm the diagnosis [5–8,10,11,13,15]) and unclear for 3 studies [9, 12, 14].

For the “flow” domain, with regard to the assessment of *H. pylori* on OAL tissue specimens, the risk of bias was considered high for one study (only 8 out of 51 patients were assessed for *H. pylori* in OAL specimens [13]) and low for the other studies. With regard to the assessment of *H. pylori* gastric infection, the risk of bias was considered high for one study (only 2 out of 5 patients were assessed [5]), unclear for two studies (number of patients assessed not clear [6], 6 of 45 patients excluded [11]), and low for the remaining studies.

Results of the risk of bias assessment are shown in Fig. 1.

Meta-Analysis

One-hundred-and-four patients were suitable for the analysis of *H. pylori* positivity in OAL tissues. Pooled *H. pylori* positivity was 16.8% (95% CI, 2.7%–59.1%) (Fig. 2). Statistical heterogeneity among studies was high ($I^2 = 77.3\%$). Considering only patients with MALT OAL, pooled *H. pylori* positivity was 22.7% (95% CI, 2.9%–74.3%), with high heterogeneity ($I^2 = 79.2\%$) (Fig. 3).

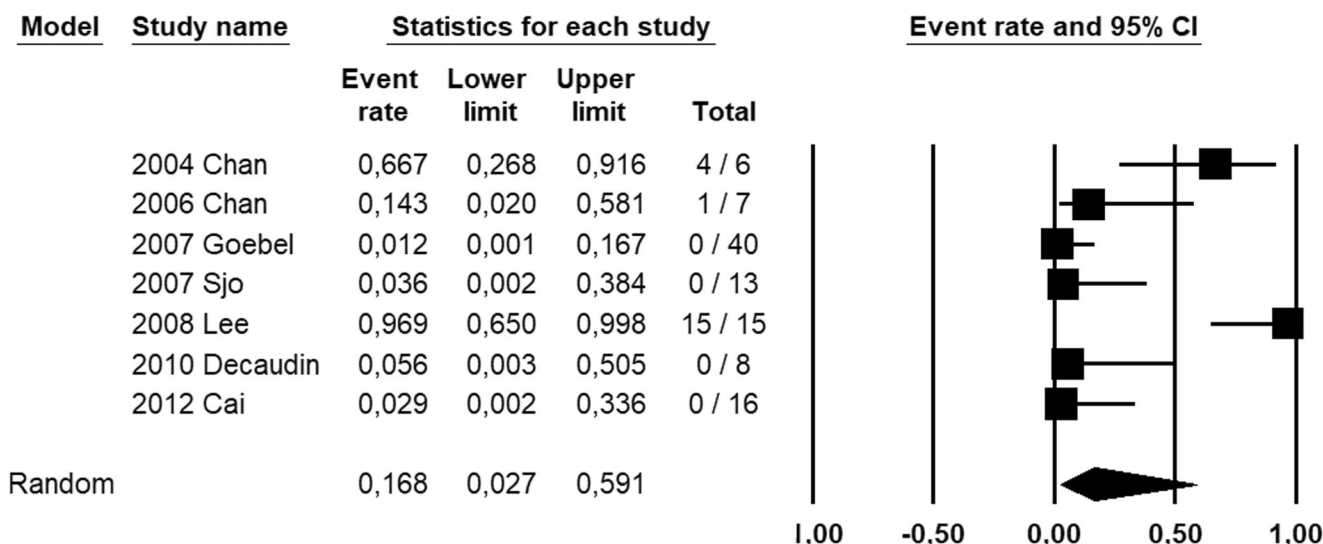


Fig. 2 Forest plot reporting the percentage of *H. pylori* positivity detected by polymerase chain reaction in ocular adnexa lymphoma tissue specimens

Two-hundred-and-twenty patients were suitable for the analysis of *H. pylori* gastric infection prevalence in patients with OAL. Pooled prevalence of *H. pylori* gastric infection was 34.7% (95% CI 26.6%–43.7%) (Fig. 4). Statistical heterogeneity among studies was low ($I^2 = 30\%$).

Discussion

This study showed that *H. pylori* positivity is detected by PCR in 16.8% of all OAL specimens and in 22.7% of MALT OALs, although with a high statistical heterogeneity among studies. On the other hand, the prevalence of *H. pylori* gastric

infection in patients with OAL was 34.7%, with low statistical heterogeneity among studies.

Most MALT lymphomas show somatic hypermutation of immunoglobulin gene variable regions, indicating that they may have undergone antigenic stimulation [30]. It is thought that local chronic stimulation of B-cells either by exogenous (e.g. infectious agents) or endogenous (e.g. autoantigen) antigens creates the background for genetic alterations which underlie the development of lymphoma [31–33]. Indeed, in our previous studies we found significant associations between autoimmune disorders and MALT lymphomas of the thyroid and salivary glands and between infectious agents and MALT OAL [34–38].

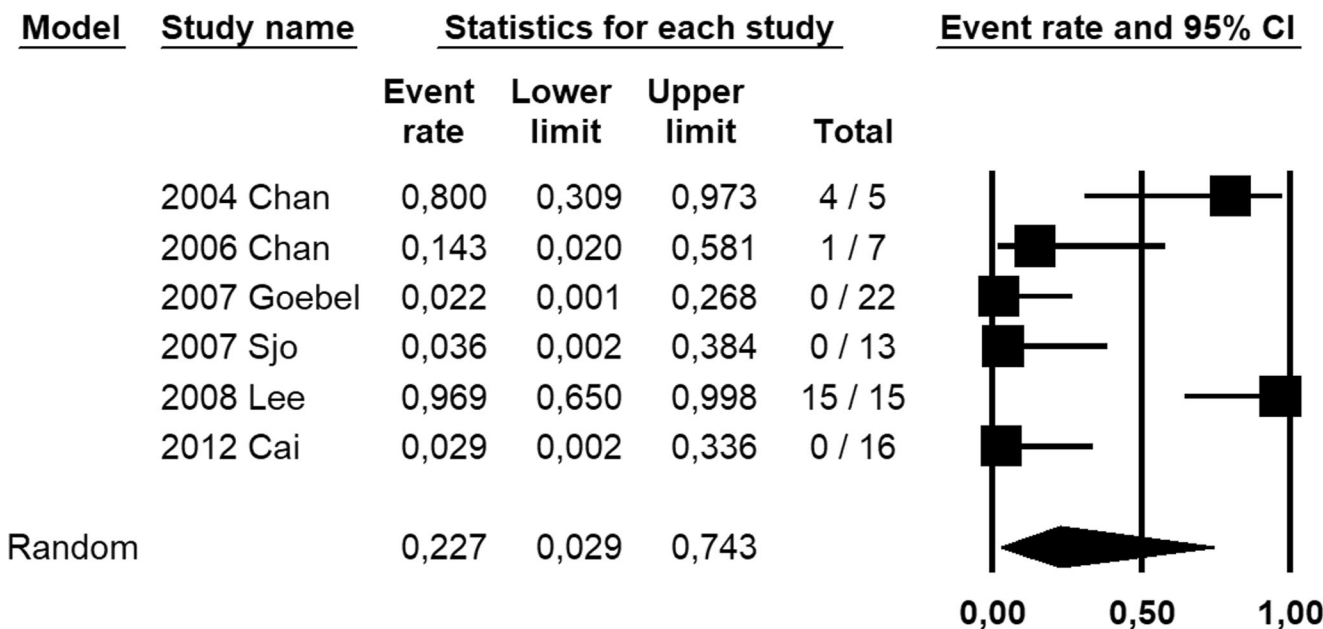


Fig. 3 Forest plot reporting the percentage of *H. pylori* positivity detected by polymerase chain reaction in MALT-type ocular adnexa lymphoma tissue specimens

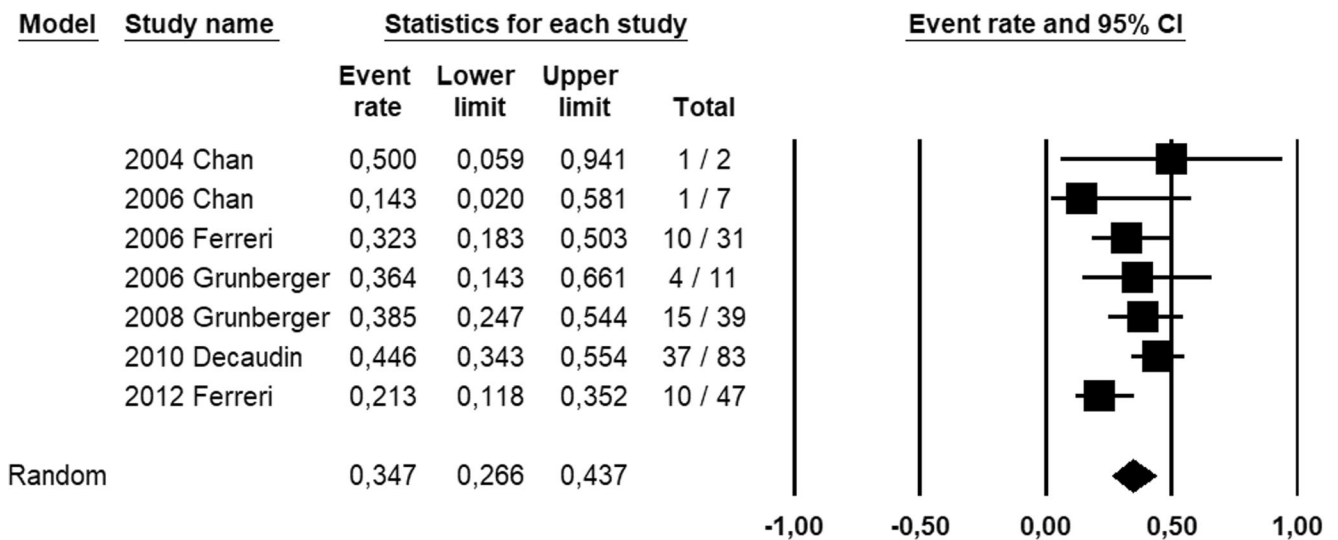


Fig. 4 Forest plot reporting the prevalence of *H. pylori* gastric infection in patients with ocular adnexa lymphoma

H. pylori is the most well-known infectious related to MALT lymphomas development, with a major etiologic role in gastric MALT lymphoma [31, 32]. The possible effects of *H. pylori* outside the stomach are less understood, but it seems to be associated with autoimmune disorders such as autoimmune thyroiditis, Henoch-Schonlein purpura and Sjögren syndrome [39].

The role of *H. pylori* in OAL has been studied since 2004, when Chan et al. reported positivity for *H. pylori* in 80% of patients with MALT OAL [5]. Our study showed that *H. pylori* DNA is detected overall in 16.8% of OAL. Despite being lower than the value initially reported by Chan et al., our result suggests the involvement of *H. pylori* in a subset of OALs. This hypothesis is strengthened by the evidence that normal conjunctival tissues, used as controls, were found to be negative for *H. pylori* [5, 12]. However, the results were extremely different among the included studies, ranging for 0% to 100% of positivity for *H. pylori*. Reasons for such heterogeneity are unclear. A possible hypothesis would be that results are affected by geographic differences. This has been shown to be true for *Chlamydia psittaci*, which is highly prevalent in OAL patients from Korea and Italy but almost absent in Japan [17, 40–49]. Regarding *H. pylori*, geographic factors were hypothesized by Lee et al. [12]. They postulated that the higher rates of positivity found in Korean patients [12] than in Danish patients [10] might reflect the higher overall prevalence of *H. pylori* infection in Korea than in Denmark [50]. However, the other available studies do not seem to confirm this hypothesis. In fact, while Chan et al. found 80% of positivity for *H. pylori* in their American series of patients with OAL [5], Cai et al. found no *H. pylori*-positive case in their Chinese series [14]; these results did not reflect the overall prevalence of *H. pylori* infection, which is sensibly lower in the USA (35.6%) than in China (55.8%) [50].

Another cause of heterogeneity might be a site-dependent involvement of *H. pylori* in OAL. The higher positivity rates were indeed found in conjunctival OALs [5, 12]; furthermore, in their OAL series Chan et al. found that *H. pylori* was positive only in conjunctival OALs, but not in an orbital OAL [4]. However, this hypothesis does not appear to be consistent, as Sjo et al. found no *H. pylori* in their series of 13 conjunctival OALs [10].

Even a histotype-dependent association cannot be an acceptable explanation; in fact, although we found that *H. pylori* positivity was more common in MALT OALs, the statistical heterogeneity among studies remained high.

Differences in the methods adopted for *H. pylori* detection, and in particular in the primers used for PCR, might also be at least in part responsible for the high heterogeneity; further studies are necessary to investigate this point.

Regarding *H. pylori* gastric infection and OAL, Decaudin et al. reported a significant association between positivity of *H. pylori* in the stomach and MALT-type OAL [13]. They postulated a mechanism of indirect infection-associated lymphomagenesis, where chronic local antigen stimulation would lead to the emergence of ectopic B cell lymphoma. In the current study, we found that the overall prevalence of *H. pylori* gastric infection in patients with OAL was 34.7%. The low statistical heterogeneity among studies gave strength to this result. Although the prevalence found is not low, it should be remarked that the overall global prevalence of *H. pylori* infection is over 50% [50]. Even considering the results according to the geographic setting, the prevalence of *H. pylori* infection was not higher than that of the national population. For example, the prevalence of 32.3% found in the Italian series assessed by Ferreri et al. [7] was lower than the overall Italian prevalence of *H. pylori* infection (56.2%) [50]. The same consideration may be made for French patients (44.6% in patients with OAL [13] vs 46.9% in the overall

national population [50]). Even in the multicenter study by Ferreri et al. [15], the prevalence found (21.3%) was lower than in any of the participating countries [50]. Given these observations, it seems unlikely that patients with *H. pylori* gastric infection may be at increased risk of OAL.

Strengths and Limitations

To the best of our knowledge, this is the first meta-analysis on the association between *H. pylori* and OAL. Given the rarity of OAL, the number of studies ($N = 11$) and patients ($N = 308$) could be considered acceptable.

Limitations of this study may lie in the different methods used for detecting *H. pylori* infection, with regard to the primers and genes used for PCR analyses (*urease B*, *vacA*, 16S rDNA) and to the diagnosis of *H. pylori* gastric infection (breath test, serology, histology, culture).

Furthermore, there were no sufficient data to perform subgroup analyses according to the country of origin and methods for *H. pylori* detection.

Conclusions

Overall, *H. pylori* positivity is found in 16.8% of all OAL specimens and in 22.7% of MALT OALs, suggesting an involvement of *H. pylori* in a subset of OALs. However, further studies are necessary to investigate the possible causes for the high heterogeneity observed, including geographic and methodological differences among studies. Regarding *H. pylori* gastric infection, its prevalence in patients with OAL is not higher than that of the general population; this does not support the possibility of an increased risk of OAL in patients with *H. pylori* gastric infection.

Compliance with Ethical Standards

Conflict of Interest The authors declare no conflict of interest.

Ethical Approval This article does not contain any studies with human participants or animals performed by any of the authors.

Informed Consent Not applicable.

References

- Sassone M, Ponzoni M, Ferreri AJ (2017) Ocular adnexal marginal zone lymphoma: Clinical presentation, pathogenesis, diagnosis, prognosis, and treatment. *Best Pract Res Clin Haematol* 30(1–2): 118–130
- Olsen TG, Heegaard S (2019) Orbital lymphoma. *Surv Ophthalmol* 64(1):45–66
- Kalogeropoulos D, Papoudou-Bai A, Kanavaros P, Kalogeropoulos C (2018) Ocular adnexal marginal zone lymphoma of mucosa-associated lymphoid tissue. *Clin Exp Med* 18(2):151–163
- Ferreri AJ, Govi S, Ponzoni M (2013) Marginal zone lymphomas and infectious agents. *Semin Cancer Biol* 23(6):431–440
- Chan CC, Smith JA, Shen DF, Ursea R, LeHoang P, Grossniklaus HE (2004) Helicobacter pylori (*H. pylori*) molecular signature in conjunctival mucosa-associated lymphoid tissue (MALT) lymphoma. *Histol Histopathol* 19(4):1219–1226
- Chan CC, Shen D, Mochizuki M, Gonzales JA, Yuen HK, Guex-Crosier Y, LeHoang P (2006) Detection of helicobacter pylori and chlamydia pneumoniae genes in primary orbital lymphoma. *Trans Am Ophthalmol Soc* 104:62–70
- Ferreri AJ, Ponzoni M, Viale E et al (2006) Association between helicobacter pylori infection and MALT-type lymphoma of the ocular adnexa: clinical and therapeutic implications. *Hematol Oncol* 24(1):33–37
- Grünberger B, Hauff W, Lukas J, Wöhrer S, Zielinski CC, Streubel B, Chott A, Raderer M (2006) 'Blind' antibiotic treatment targeting chlamydia is not effective in patients with MALT lymphoma of the ocular adnexa. *Ann Oncol* 17(3):484–487
- Goebel N, Serr A, Mittelviehhaus H, Reinhard T, Bogdan C, Auw-Haedrich C (2007) Chlamydia psittaci, helicobacter pylori and ocular adnexal lymphoma—is there an association? The German experience. *Leuk Res* 31(10):1450–1452
- Sjö NC, Foegh P, Juhl BR, Nilsson HO, Prause JU, Ralfkiær E, Wadström T, Heegaard S (2007) Role of helicobacter pylori in conjunctival mucosa-associated lymphoid tissue lymphoma. *Ophthalmology*. 114(1):182–186
- Gruenberger B, Woehrer S, Troch M, Hauff W, Lukas J, Streubel B, Muellauer L, Chott A, Raderer M (2008) Assessment of the role of hepatitis C, helicobacter pylori and autoimmunity in MALT lymphoma of the ocular adnexa in 45 Austrian patients. *Acta Oncol* 47(3):355–359
- Lee SB, Yang JW, Kim CS (2008) The association between conjunctival MALT lymphoma and helicobacter pylori. *Br J Ophthalmol* 92(4):534–536
- Decaudin D, Ferroni A, Vincent-Salomon A, Beldjord K, Validire P, de Cremoux P, Validire P, Plancher C, Mathiot C, Macintyre E, Asselain B, Girodet J, Mal F, Brousse N, Beretti JL, Dendale R, Lumbroso-le Rouic L, Hermine O, Lecuit M (2010) Ocular adnexal lymphoma and helicobacter pylori gastric infection. *Am J Hematol* 85(9):645–649
- Cai JP, Cheng JW, Ma XY, Li YZ, Li Y, Huang X, Wei RL (2012) Lack of association of conjunctival MALT lymphoma with Chlamydiae or helicobacter pylori in a cohort of Chinese patients. *Med Sci Monit* 18(2):BR84–BR88
- Ferreri AJ, Govi S, Pasini E et al (2012) Chlamydia psittaci eradication with doxycycline as first-line targeted therapy for ocular adnexal lymphoma: final results of an international phase II trial. *J Clin Oncol* 30(24):2988–2994
- Ferreri AJ, Ponzoni M, Guidoboni M et al (2005) Regression of ocular adnexal lymphoma after Chlamydia psittaci-eradicating antibiotic therapy. *J Clin Oncol* 23(22):5067–5073
- Ferreri AJ, Ponzoni M, Guidoboni M et al (2006) Bacteria-eradicating therapy with doxycycline in ocular adnexal MALT lymphoma: a multicenter prospective trial. *J Natl Cancer Inst* 98(19):1375–1382
- Zelenetz AD, Gordon LI, Abramson JS, et al. NCCN Clinical Practice Guidelines in Oncology (NCCN Guidelines®) – B-Cell Lymphomas. Version 4.2019 – May 6, 2019
- Lionetti R, De Luca M, Travaglini A et al (2019) Treatments and overall survival in patients with Krukenberg tumor. *Arch Gynecol Obstet* 300:15–23. <https://doi.org/10.1007/s00404-019-05167-z>
- Raffone A, Travaglini A, Saccone G, Cieri M, Mascolo M, Mollo A, Insabato L, Zullo F (2019) Diagnostic and prognostic value of

- ARID1A in endometrial hyperplasia: a novel marker of occult cancer. *APMIS*. 127:597–606. <https://doi.org/10.1111/apm.12977>
21. Raffone A, Travaglini A, Saccone G, D'Alessandro P, Arduino B, Mascolo M, de Placido G, Insabato L, Zullo F (2019) Diabetes mellitus is associated with occult Cancer in endometrial hyperplasia. *Pathol Oncol Res* 26:1377–1384. <https://doi.org/10.1007/s12253-019-00684-3>
 22. Moher D, Shamseer L, Clarke M et al (2015) Preferred reporting items for systematic review and meta-analysis protocols (PRISMA-P) 2015 statement. *Syst Rev* 4:1
 23. Whiting PF, Rutjes AW, Westwood ME et al (2011) QUADAS-2: a revised tool for the quality assessment of diagnostic accuracy studies. *Ann Intern Med* 155(8):529–536
 24. Raffone A, Travaglini A, Saccone G, Alviggi C, Mascolo M, de Placido G, Insabato L, Mollo A, Zullo F (2019) Management of women with atypical polypoid adenomyoma of the uterus: a quantitative systematic review. *Acta Obstet Gynecol Scand* 98:842–855. <https://doi.org/10.1111/aogs.13553>
 25. Travaglini A, Raffone A, Saccone G, de Luca C, Mollo A, Mascolo M, de Placido G, Insabato L, Zullo F (2019) Immunohistochemical nuclear expression of β -catenin as a surrogate of CTNNB1 exon 3 mutation in endometrial Cancer. *Am J Clin Pathol* 151(5):529–538. <https://doi.org/10.1093/ajcp/aqy178>
 26. Travaglini A, Raffone A, Saccone G, Mascolo M, Pignatiello S, Mollo A, de Placido G, Insabato L, Zullo F (2019) PTEN immunohistochemistry in endometrial hyperplasia: which are the optimal criteria for the diagnosis of precancer? *APMIS*. 127(4):161–169
 27. Raffone A, Travaglini A, Saccone G, Mascolo M, Insabato L, Mollo A, de Placido G, Zullo F (2019) PAX2 in endometrial carcinogenesis and in differential diagnosis of endometrial hyperplasia. A systematic review and meta-analysis of diagnostic accuracy. *Acta Obstet Gynecol Scand* 98(3):287–299
 28. Travaglini A, Raffone A, Saccone G, Mollo A, de Placido G, Mascolo M, Insabato L, Zullo F (2019) Complexity of glandular architecture should be reconsidered in the classification and management of endometrial hyperplasia. *APMIS*. 127:427–434. <https://doi.org/10.1111/apm.12945>
 29. Raffone A, Travaglini A, Saccone G, di Maio A, Mollo A, Mascolo M, de Rosa R, de Placido G, Insabato L, Zullo F (2019) Diabetes mellitus and responsiveness of endometrial hyperplasia and early endometrial cancer to conservative treatment. *Gynecol Endocrinol* 5:1–6. <https://doi.org/10.1080/09513590.2019.1624716>
 30. Qin Y, Greiner A, Trunk MJ, Schmausser B, Ott MM, Muller-Hermelink HK (1995) Somatic hypermutation in low-grade mucosa-associated lymphoid tissue-type B-cell lymphoma. *Blood* 86:3528–3534
 31. Parsonnet J, Isaacson PG (2004) Bacterial infection and MALT lymphoma. *N Engl J Med* 350:213–215
 32. Parsonnet J, Hansen S, Rodriguez L, Gelb AB, Warnke RA, Jellum E, Orentreich N, Vogelmann JH, Friedman GD (1994) Helicobacter pylori infection and gastric lymphoma. *N Engl J Med* 330:1267–1271
 33. Yamasaki R, Yokota K, Okada H, Hayashi S, Mizuno M, Yoshino T, Hirai Y, Saitou D, Akagi T, Oguma K (2004) Immune response in helicobacter pylori-induced low-grade gastric-mucosa-associated lymphoid tissue (MALT) lymphoma. *J Med Microbiol* 53:21–29
 34. Travaglini A, Pace M, Varricchio S, Insabato L, Giordano C, Picardi M, Pane F, Staibano S, Mascolo M (2020) Hashimoto thyroiditis in primary thyroid non-Hodgkin lymphoma. *Am J Clin Pathol* 153(2):156–164
 35. Travaglini A, Pace M, Varricchio S, Insabato L, Picardi M, Severino A, Pane F, Staibano S, Mascolo M (2020) Clinical features associated with high pathological grade in primary thyroid lymphoma. *Pathol Res Pract* 216(3):152819
 36. Travaglini A, Giordano C, Pace M, Varricchio S, Picardi M, Pane F, Staibano S, Mascolo M (2020) Sjögren syndrome in primary salivary gland lymphoma. *Am J Clin Pathol* 153(6):719–724
 37. Travaglini A, Pace M, Varricchio S, Della Pepa R, Iuliano A, Picardi M, Pane F, Staibano S, Mascolo M (2020) Prevalence of chlamydia psittaci, chlamydia pneumoniae, and chlamydia trachomatis determined by molecular testing in ocular adnexa lymphoma specimens. *Am J Clin Pathol* 153(4):427–434
 38. Travaglini A, Varricchio S, Pace M, Iuliano A, Picardi M, Tranfa F, Staibano S, Mascolo M (2020) Hepatitis C virus in MALT-lymphoma of the ocular adnexa. *Pathol Res Pract* 216(4):152864
 39. Gasbarrini A, Franceschi F (1999) Autoimmune diseases and helicobacter pylori infection. *Biomed Pharmacother* 53:223–226
 40. Ferreri AJ, Guidoboni M, Ponzoni M et al (2004) Evidence for an association between chlamydia psittaci and ocular adnexal lymphomas. *J Natl Cancer Inst* 96(8):586–594
 41. Ferreri AJ, Dolcetti R, Dognini GP et al (2008) Chlamydia psittaci is viable and infectious in the conjunctiva and peripheral blood of patients with ocular adnexal lymphoma: results of a single-center prospective case-control study. *Int J Cancer* 123(5):1089–1093
 42. Daibata M, Nemoto Y, Togitani K, Fukushima A, Ueno H, Ouchi K, Fukushi H, Imai S, Taguchi H (2006) Absence of chlamydia psittaci in ocular adnexal lymphoma from Japanese patients. *Br J Haematol* 132(5):651–652
 43. Liu YC, Ohyashiki JH, Ito Y, Iwaya KI, Serizawa H, Mukai K, Goto H, Usui M, Ohyashiki K (2006) Chlamydia psittaci in ocular adnexal lymphoma: Japanese experience. *Leuk Res* 30(12):1587–1589
 44. Yakushiji Y, Kodama T, Takaoka I, Tanimoto K, Bessho H, Sakai I, Hato T, Hasegawa H, Yasukawa M (2007) Absence of chlamydial infection in Japanese patients with ocular adnexal lymphoma of mucosa-associated lymphoid tissue. *Int J Hematol* 85(3):223–230
 45. Usui Y, Rao NA, Takase H, Tsubota K, Umazume K, Diaz-Aguilar D, Kezuka T, Mochizuki M, Goto H, Sugita S (2016) Comprehensive polymerase chain reaction assay for detection of pathogenic DNA in lymphoproliferative disorders of the ocular adnexa. *Sci Rep* 6:36621
 46. Yoo C, Ryu MH, Huh J, Park JH, Kang HJ, Ahn HS, Lee Y, Kim MJ, Lee H, Kim TW, Chang HM, Lee JL, Kang YK (2007) Chlamydia psittaci infection and clinicopathologic analysis of ocular adnexal lymphomas in Korea. *Am J Hematol* 82(9):821–823
 47. Choung HK, Kim YA, Lee MJ, Kim N, Khwang SI (2012) Multigene methylation analysis of ocular adnexal MALT lymphoma and their relationship to Chlamydia psittaci infection and clinical characteristics in South Korea. *Invest Ophthalmol Vis Sci* 53(4):1928–1935
 48. Lee MJ, Min BJ, Choung HK, Kim N, Kim YA, Khwang SI (2014) Genome-wide DNA methylation profiles according to Chlamydia psittaci infection and the response to doxycycline treatment in ocular adnexal lymphoma. *Mol Vis* 20:1037–1047
 49. Kim TM, Kim KH, Lee MJ, Jeon YK, Lee SH, Kim DW, Kim CW, Kim IH, Khwang SI, Heo DS (2010) First-line therapy with doxycycline in ocular adnexal mucosa-associated lymphoid tissue lymphoma: a retrospective analysis of clinical predictors. *Cancer Sci* 101(5):1199–1203
 50. Hooi JKY, Lai WY, Ng WK, Suen MMY, Underwood FE, Tanyingoh D, Malfertheiner P, Graham DY, Wong VWS, Wu JCY, Chan FKL, Sung JY, Kaplan GG, Ng SC (2017) Global prevalence of helicobacter pylori infection: systematic review and meta-analysis. *Gastroenterology*. 153(2):420–429