



TCGA Classification of Endometrial Cancer: the Place of Carcinosarcoma

Antonio Travaglino¹ · Antonio Raffone² · Annarita Gencarelli¹ · Antonio Mollo² · Maurizio Guida² · Luigi Insabato¹ · Angela Santoro³ · Gian Franco Zannoni³ · Fulvio Zullo²

Received: 29 November 2019 / Accepted: 21 May 2020 / Published online: 29 May 2020
© Arányi Lajos Foundation 2020

Abstract

In 2013, The Cancer Genome Atlas (TCGA) Research Network found four novel prognostic subgroups of endometrial carcinoma: POLE/ultramutated (POLE), microsatellite-unstable/hypermethylated (MSI), copy-number-low/TP53-wild-type (CNL), and copy-number-high/TP53-mutant (CNH). However, poor is known regarding uncommon histotypes of endometrial cancer. We aimed to assess the genetic profile of uterine carcinosarcoma (UCS) on the light of these findings. A systematic review and meta-analysis was performed through electronic databases searching (up to July 2019). All studies assessing UCS series for the TCGA classification were included. For each TCGA subgroup, pooled prevalence on the total UCS number was calculated. Four studies with 231 patients were included. Pooled prevalence of the TCGA subgroups were: 5.3% for the POLE subgroup, 7.3% for the MSI subgroup, 73.9% for the CNH subgroup, 13.5% for the CNL subgroup. The CNH subgroup predominates in UCS, while subgroups with high mutational load (POLE and MSI) are less common. UCS appears as a preferential evolution of CNH carcinomas.

Keywords Cancer · Endometrium · Prognosis · Risk assessment · PROMISE · Treatment · Endometrium

Introduction

Endometrial carcinoma is the most common gynecological malignancy in developed countries [1–5]. The management of patients with endometrial carcinoma is mainly based on pathologic findings, such as histotype, tumor grade and

stage and lymph-vascular space invasion [6]. However, pathologic assessment has shown poor reproducibility, and many authors think that this limitation is at the basis of the increased mortality observed in endometrial cancer in the last decades [7, 8].

Since the publication of The Cancer Genome Atlas (TCGA) data in 2013, it has been shown that specific molecular features have a major prognostic value in endometrial carcinoma. In fact, endometrial carcinomas can be consistently subdivided into four prognostic molecular subgroups: POLE/ultramutated (POLE), microsatellite-unstable/hypermethylated (MSI), copy-number-low/TP53-wild-type (CNL), and copy-number-high/TP53-mutant (CNH) [9–15]. Although molecular analyses used by the TCGA were complex and expensive, it has been shown that such classification can be reproduced by using immunohistochemistry for p53 and mismatch repair proteins and POLE sequencing [10–12].

Given these findings, criteria for the management of endometrial carcinoma will probably be strongly revised in the near future [16]. However, several aspects still have to be clarified, e.g. how tumor histotype should be integrated with molecular data. This point is unclear especially for uncommon histotypes of endometrial cancer, such as undifferentiated/

Electronic supplementary material The online version of this article (<https://doi.org/10.1007/s12253-020-00829-9>) contains supplementary material, which is available to authorized users.

✉ Antonio Raffone
anton.raffone@gmail.com

- ¹ Anatomic Pathology Unit, Department of Advanced Biomedical Sciences, School of Medicine, University of Naples Federico II, Naples, Italy
- ² Gynecology and Obstetrics Unit, Department of Neuroscience, Reproductive Sciences and Dentistry, School of Medicine, University of Naples Federico II, Via Sergio Pansini, 5, 80131 Naples, Italy
- ³ Pathology Unit, Department of Woman and Child Health, Agostino Gemelli University Polyclinic, Catholic University of the Sacred Heart, Rome, Italy

dedifferentiated carcinoma (UDC/DDC), clear cell carcinoma and mucinous carcinoma.

In this review, we assessed in particular uterine carcinosarcoma (UCS), which had previously been considered as a type of uterine sarcoma and is now regarded as a “high-risk histology” of endometrial carcinoma [6, 17]. We aimed to assess the immunohistochemical/molecular profile of UCS in the light of the TCGA findings, through a systematic review and meta-analysis.

Materials and Methods

Study Protocol

The study protocol, i.e. the methods for systematic review and meta-analyses, were defined a priori, based on our previous studies [18–20]. Each review stage was performed by tree authors (AT, AR, AM) independently, and all authors were consulted in the case of disagreements. Authors followed The Preferred Reporting Item for Systematic Reviews and Meta-analyses (PRISMA) statement to report this review [21].

Search Strategy and Study Selection

Seven different electronic databases were searched: EMBASE, Scopus, MEDLINE, Web of Sciences, Google Scholar, ClinicalTrials.gov and Cochrane Library. In each database, the search was performed from the database inception to May 2019, by using the following combination of text words: (endometrial OR endometrium OR uterine) AND (carcinosarcoma OR sarcomatoid carcinoma OR malignant mixed müllerian tumor). The research was subsequently updated to October 2019. References from relevant studies were also reviewed.

All peer-reviewed studies assessing UCS series for the TCGA classification were included. The following exclusion criteria, defined a priori, were adopted: sample size <10; incomplete TCGA classification (i.e. not all TCGA subgroup were investigated); sample size <10; reviews.

Data Extraction and Risk of Bias within Studies Assessment

Main data extracted were: the total number of UCS and the number of UCS in each TCGA subgroup; UCS were assigned to a specific TCGA subgroup based on the hierarchical model proposed by the TCGA [9] or the ProMisE [10–12] was used to assign. Four domains related to the risk of bias were assessed following the QUADAS-2 [22–25]: 1) Patient selection (i.e. if patients were consecutively selected); 2) Index test (i.e. if methods for immunohistochemical/molecular analyses are clearly described); 3) Reference standard (i.e. if cases were

reviewed by expert pathologists to confirm the UCS histotype); 4) Flow (i.e. if $\geq 95\%$ of included patients were assessed for the TCGA classification). Concerns about applicability of the domains 1, 2 and 3 were also assessed.

For each domain, the risk of bias was considered “low”, “unclear” or “high”, as previously described [26–29].

Data Analysis

The prevalence of each TCGA subgroup in UCS was calculated as the number of UCSs showing the molecular signature of that subgroup by the total number of UCSs. Data were pooled by using the random effect model of DerSimonian-Laird. Results for each individual study and pooled estimates were graphically reported on forest plots with 95% confidence interval (CI). Since the CNL subgroup is defined by the absence of the markers of the other 3 subgroups, its prevalence was calculated as follows: $\%CNL = 100\% - (\%POLE + \%MSI + \%CNH)$.

Statistical heterogeneity among studies was quantified according to the inconsistency index I^2 : heterogeneity was categorized as null ($I^2 = 0\%$), minimal ($0 < I^2 < 25\%$), low ($25 \leq I^2 < 50\%$), moderate ($50 \leq I^2 < 75\%$) or high ($I^2 \geq 75\%$), as previously described [30–34].

Data analysis was performed by using Comprehensive Meta-Analysis (Biostat, 14 North Dean Street, Englewood, NJ 07631, USA) and Review Manager 5.3 (Copenhagen: The Nordic Cochrane Centre, Cochrane Collaboration, 2014).

Results

Study Selection

After the exclusion of non-relevant studies, 13 articles [16, 35–46] were full-text assessed for eligibility: 8 studies were excluded for incomplete TCGA assessment [35–42]; one study was excluded for overlapping patient data with a study already included [43] and another study was excluded for being a review [16]. Finally, 3 studies fulfilled inclusion criteria and thus were included [44–46]. The updated research led to the inclusion of a fourth study [47]. The process of study selection schematically reported in Figure S1.

Study Characteristics

The overall sample was constituted of 231 patients with UCS. The POLE group was assessed by performing *POLE* sequencing in all studies; the MSI group was assessed by molecular analysis in three studies [45–47] and by mismatch repair proteins immunohistochemistry in the remaining study [44]; the CNH subgroup was assessed by using DNA copy number analysis in one study (which also performed *TP53*

Table 1 Characteristics of the included studies

Study	Country	Period of Enrollment	Sample size	Methods to assess TCGA subgroups			
				POLE	MSI	CNH	CNL
McConechy et al. 2015 [44]	Canada	unclear	30	<i>POLE</i> sequencing	mismatch repair proteins immunohistochemistry	p53 immunohistochemistry, <i>TP53</i> sequencing	exclusion
Cherniack et al. 2017 [45]	USA	unclear	57	<i>POLE</i> sequencing	microsatellite instability testing	<i>TP53</i> sequencing	exclusion
Le Gallo et al. 2018 [46]	USA	unclear	53	<i>POLE</i> sequencing	microsatellite instability testing	<i>TP53</i> sequencing	exclusion
Gotoh 2019 [47]	Japan	1998–2015	91	<i>POLE</i> sequencing	microsatellite instability testing	DNA copy number analysis	exclusion

POLE: POLE/ultramutated subgroup; MSI: microsatellite-instable/hypermutated subgroup; CNH: copy-number-high/*TP53*-mutant subgroup; CNL: copy-number-low/*TP53*-wild-type subgroup

sequencing) [47], and *TP53* sequencing in the remaining studies, one of which also performed p53 immunohistochemistry [44]. General characteristics of the included studies are shown in Table 1.

Risk of Bias within Studies Assessment

The risk of bias for the “patient selection” domain was considered low for one study (period of enrollment and inclusion criteria reported [47]) and unclear in the remaining studies. For all the other domains, no risks of bias were highlighted and thus all studies were considered at low risk. No concerns about applicability were raised. Results of the risk of bias assessment are summarized in Figure S2.

Meta-Analysis

Among all UCS patients, 5.3% (95% CI, 2.1%–12.5%) belonged to the POLE subgroup (Fig. 1), with low statistical heterogeneity among studies ($I^2 = 45.9%$); 7.3% (95% CI, 2.2%–21.6%) belonged to the MSI subgroup (Fig. 2), with high heterogeneity ($I^2 = 78.7%$); 73.9% (95% CI, 58.1%–85.2%) belonged to the CNH subgroup (Fig. 3), with high heterogeneity ($I^2 = 80.2%$). The remaining 13.5% was assigned to the CNL subgroup.

Discussion

This study showed that 5.3% of UCS were POLE, 7.3% were MSI, 73.9% were CNH and 13.5% were CNL. To the best of our knowledge, this is the first meta-analysis focused on the molecular background of UCS.

UCS, also called malignant mixed Müllerian tumor, is an aggressive uterine neoplasm constituted by a carcinomatous component and a sarcomatous component. The carcinomatous component often is high-grade and may display features of any endometrial carcinoma histotype (i.e. endometrioid, serous, clear cell), while the sarcomatous component may be homologous or heterologous based on the type of mesenchymal differentiation. Based on molecular studies, the sarcomatous component is now considered as a metaplastic change of the carcinomatous component, through a process of epithelial-to-mesenchymal transition [17]. Therefore, UCS is listed among the “high-risk histologies” of endometrial carcinoma [6] and is considered the most aggressive histotype together with UDC/DDC [48–52]. Indeed, the NCCN guidelines recommend chemo/radiotherapy for these two histotypes even in the earliest stages and in the absence of residual tumor in the hysterectomy specimen [6].

Given the outstanding prognostic value of the TCGA classification [9], it appears crucial to assess the several histotypes

Fig. 1 Forest plot reporting the prevalence of the POLE/ultramutated subgroup in uterine carcinosarcoma

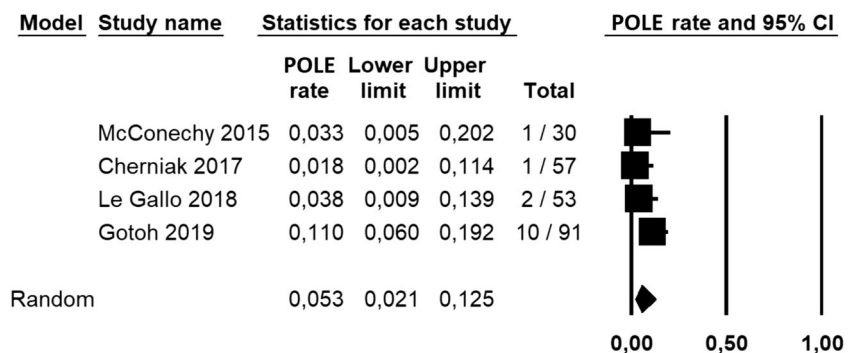
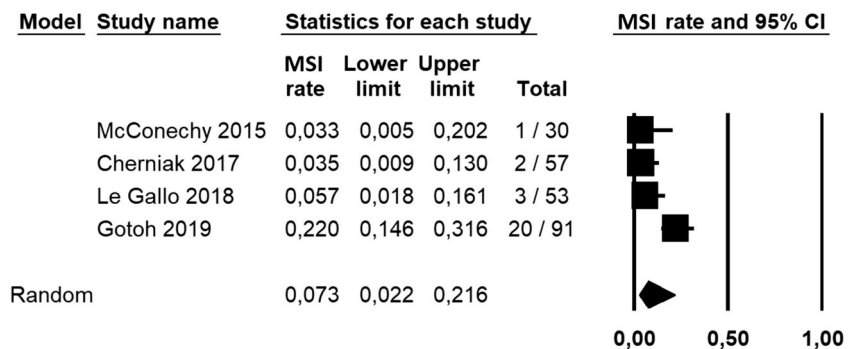


Fig. 2 Forest plot reporting the prevalence of the MSI/hypermutated subgroup in uterine carcinosarcoma



of endometrial carcinoma in the light of such classification. However, while the TCGA subgroups have repeatedly been assessed in endometrioid and serous carcinoma [10–15], their distribution in less common histotypes is less clear.

Our study showed that the CNH subgroup predominated in UCS, while hypermutated and ultramutated tumors were rare.

This evidence marks a crucial difference between the two histotypes with the worst prognosis, i.e. UCS and UDC/DDC. Indeed, while most UDC/DDCs show a high mutational rate, with a large predominance of the MSI subgroup [53–58], the majority of UCSs are tumors with low mutational rates and high copy-number-alteration. This evidence may have several implications.

First, such a molecular difference may be helpful in the differential diagnosis between UDC/DDC and UCS, which is sometimes difficult. In fact, both histotypes can show a biphasic pattern with an epithelial and a non-epithelial component [59]. In difficult cases, immunohistochemistry for mismatch repair proteins (surrogate for MSI testing) and for p53 (surrogate for copy-number assessment) may aid the pathologist.

Second, it may be hypothesized that UDC/DDC and UCS might represent the final evolution of MSI/POLE endometrioid carcinomas and of CNH carcinomas (of any histotype), respectively (Fig. 4). In fact, it has been reported that both the sarcomatous component of UCS and the undifferentiated component of UDC/DDC express the same

markers of epithelial-to-mesenchymal transition; such finding suggests that the same molecular event could turn an endometrial carcinoma into an UCS or an UDC/DDC depending on its baseline features [42]. In this regard, the TCGA groups might account for the different evolution.

Third, the different molecular background might reflect major prognostic difference between these two histotypes. In fact, studies on high-grade endometrial carcinomas have shown that MSI and POLE signatures are associated with a significant improvement in the prognosis [60, 61]. On the other hand, the CNH signature is consistently associated with the worst prognosis among endometrial carcinomas [9–15]. These molecular signatures might maintain their prognostic value in UCS and UDC/DDC [47, 57].

Finally, the molecular difference between UCS and UDC/DDC might be translated into different treatment strategies between these two histotypes, which are currently treated with the same protocol as recommended by the NCCN guidelines [6]. In particular, the high mutational load may support the use of immunotherapy in most UDC/DDC [62].

Further studies are needed to assess the feasibility of a differential approach based on molecular signatures, since our study is limited by the low number of included studies and by the lack of prognostic data. However, the consistency among the results found may strengthen the basis for future investigations in this field.

Fig. 3 Forest plot reporting the prevalence of the copy-number-high subgroup in endometrial clear cell carcinoma

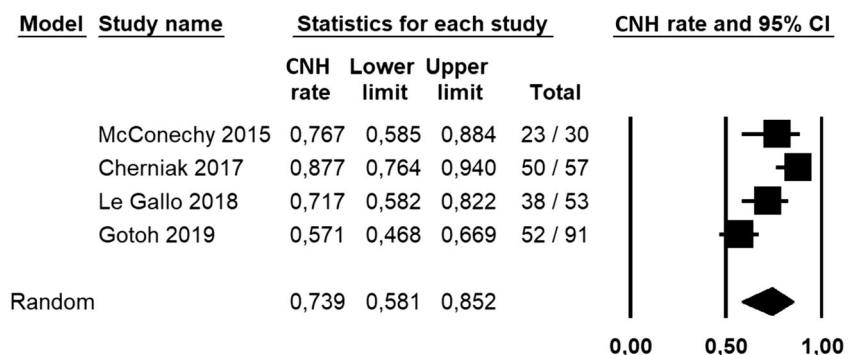
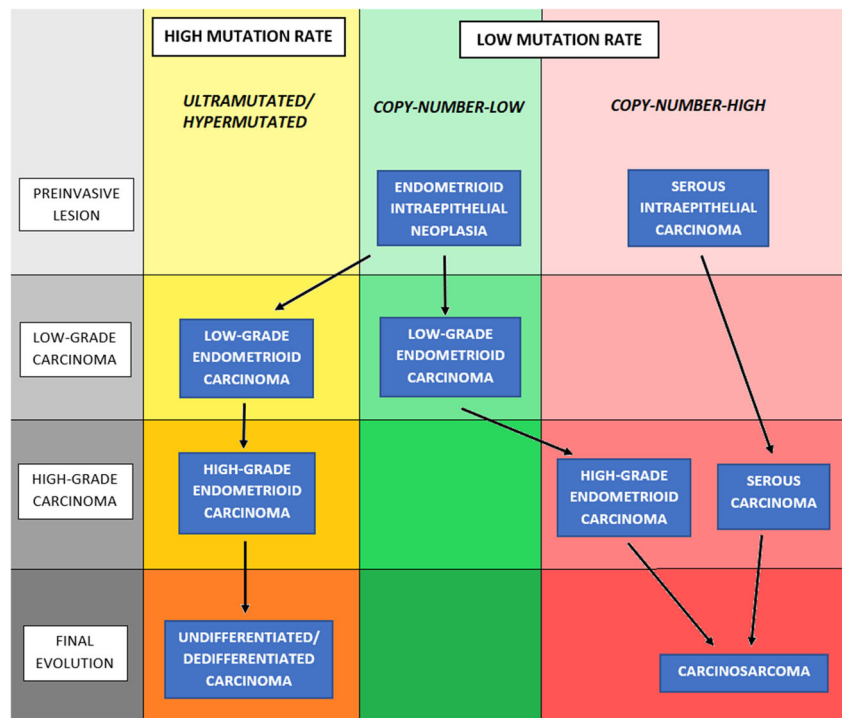


Fig. 4 Flow diagram schematically reporting the hypothetical dual final evolution of endometrial carcinoma, towards undifferentiated carcinoma (in subgroups with high mutational rate, i.e. POLE/ultramutated and MSI/hypermutable) or carcinosarcoma (in subgroups with low-mutational rate, i.e. copy-number-low and copy-number-high)



Conclusion

UCS is mostly constituted of CNH tumors, suggesting that UCS is a preferential evolution of CNH carcinomas. On the other hand, subgroups with high mutational load (i.e. POLE and MSI subgroups) are less common. This evidence could mark a crucial difference with the other highly-aggressive histotype of endometrial carcinoma, i.e. UDC/DDC, which is mainly composed of highly mutated tumors instead. Such a molecular difference may aid in the biologic, diagnostic and prognostic definition of these two histotypes, suggesting the possibility of a differential treatment between these two histotypes, which are currently treated with the same protocol. Further studies are necessary to define the clinical implications of these findings.

Author's Contribution AT, AR and AM independently assessed electronic search, eligibility of the studies, inclusion criteria, risk of bias, data extraction and data analysis. Disagreements were resolved by discussion with other authors (AG, MG, LI, AS, GFZ, FZ). MG, AM and LI contributed to the elaboration of methods for risk of bias assessment, data extraction and analysis. AT, AR and FZ conceived the study; AG, MG, LI and FZ worked on the design of the study; AT, AR, AG, AM, LI, GFZ and FZ worked on the manuscript preparation; LI, GFZ and FZ supervised the whole study.

Compliance with Ethical Standards

Conflict of Interest Authors report no conflict of interest.

References

1. Siegel RL, Miller KD, Jemal A (2015) Cancer statistics, 2015. *CA Cancer J Clin* 65(1):5–29
2. Raffone A, Travaglino A, Mascolo M, Carbone L, Guida M, Insabato L, Zullo F (2019) TCGA molecular groups of endometrial cancer: pooled data about prognosis. *Gynecol Oncol* 155(2):374–383
3. Travaglino A, Raffone A, Saccone G, de Luca C, Mollo A, Mascolo M, de Placido G, Insabato L, Zullo F (2019) Immunohistochemical nuclear expression of β -catenin as a surrogate of CTNNB1 exon 3 mutation in endometrial Cancer. *Am J Clin Pathol* 151(5):529–538
4. Raffone A, Travaglino A, Santoro A, Esposito I, Angelico G, Spadola S, Zannoni GF (2019) Accuracy of one-step nucleic acid amplification in detecting lymph node metastases in endometrial cancer. *Pathol Oncol Res*. <https://doi.org/10.1007/s12253-019-00727-9>
5. Travaglino A, Raffone A, Saccone G, Insabato L, Mollo A, de Placido G, Zullo F (2019) Immunohistochemical predictive markers of response to conservative treatment of endometrial hyperplasia and early endometrial cancer: a systematic review. *Acta Obstet Gynecol Scand* 98:1086–1099. <https://doi.org/10.1111/aogs.13587>
6. Abu-Rustum NR, Yashar CM, Bean S, et al. NCCN Clinical Practice Guidelines in Oncology (NCCN Guidelines®) – Uterine neoplasms. Version 3.2019 – February 11, 2019
7. Hoang LN, McConechy MK, Kobel M et al (2013) Histotype-genotype correlation in 36 high-grade endometrial carcinomas. *Am J Surg Pathol* 37:1421–1432
8. Gilks CB, Oliva E, Soslow RA (2013) Poor interobserver reproducibility in the diagnosis of high-grade endometrial carcinoma. *Am J Surg Pathol* 37:874–881
9. Cancer Genome Atlas Research Network et al (2013) Integrated genomic characterization of endometrial carcinoma. *Nature* 497(7447):67–73

10. Talhouk A, McConechy MK, Leung S et al (2015) A clinically applicable molecular-based classification for endometrial cancers. *Br J Cancer* 113(2):299–310
11. Talhouk A, McConechy MK, Leung S et al (2017) Confirmation of ProMisE: a simple, genomics-based clinical classifier for endometrial cancer. *Cancer* 123(5):802–813
12. Kommoss S, McConechy MK, Kommoss F et al (2018) Final validation of the ProMisE molecular classifier for endometrial carcinoma in a large population-based case series. *Ann Oncol* 29(5):1180–1188
13. Stelloo E, Nout RA, Osse EM, Jürgenliemk-Schulz IJ, Jobsen JJ, Lutgens LC, van der Steen-Banasik EM, Nijman HW, Putter H, Bosse T, Creutzberg CL, Smit VTHBM (2016) Improved risk assessment by integrating molecular and clinicopathological factors in early-stage endometrial cancer-combined analysis of the PORTEC cohorts. *Clin Cancer Res* 22(16):4215–4224
14. Bosse T, Nout RA, McAlpine JN et al (2018) Molecular classification of grade 3 endometrioid endometrial cancers identifies distinct prognostic subgroups. *Am J Surg Pathol* 42(5):561–568
15. Cosgrove CM, Trichtler DL, Cohn DE et al (2018) An NRG oncology/GOG study of molecular classification for risk prediction in endometrioid endometrial cancer. *Gynecol Oncol* 148(1):174–180
16. Leskela S, Pérez-Mies B, Rosa-Rosa JM, Cristobal E, Biscuola M, Palacios-Berraquero ML, Ong S, Matias-Guiu X, Palacios J (2019) Molecular basis of tumor heterogeneity in endometrial carcinosarcoma. *Cancers (Basel)* 11(7):964
17. McAlpine J, Leon-Castillo A, Bosse T (2018) The rise of a novel classification system for endometrial carcinoma; integration of molecular subclasses. *J Pathol* 244(5):538–549
18. Raffone A, Travaglino A, Saccone G, Alviggi C, Mascolo M, De Placido G, Insabato L, Mollo A, Zullo F (2019) Management of women with atypical polypoid adenomyoma of the uterus: a quantitative systematic review. *Acta Obstet Gynecol Scand* 98(7):842–855
19. Raffone A, Travaglino A, Saccone G et al (2019) Should progesterone and estrogens receptors be assessed for predicting the response to conservative treatment of endometrial hyperplasia and cancer? A systematic review and meta-analysis. *Acta Obstet Gynecol Scand* 98(8):976–987
20. Lionetti R, De Luca M, Travaglino A, Raffone A, Insabato L, Saccone G, Mascolo M, D'armiento M, Zullo F, Corcione F (2019) Treatments and overall survival in patients with Krukenberg tumor. *Arch Gynecol Obstet* 300(1):15–23
21. Moher D, Shamseer L, Clarke M et al (2015) Preferred reporting items for systematic review and meta-analysis protocols (PRISMA-P) 2015 statement. *Syst Rev* 4:1
22. Whiting PF, Rutjes AW, Westwood ME, Mallett S, Deeks JJ, Reitsma JB, Leeflang MM, Sterne JA, Bossuyt PM, QUADAS-2 Group (2011) QUADAS-2: a revised tool for the quality assessment of diagnostic accuracy studies. *Ann Intern Med* 155(8):529–536
23. Raffone A, Travaglino A, Saccone G, Viggiani M, Giampaolino P, Insabato L, Mollo A, de Placido G, Zullo F (2019) PTEN expression in endometrial hyperplasia and risk of cancer: a systematic review and meta-analysis. *Arch Gynecol Obstet* 299(6):1511–1524
24. Travaglino A, Raffone A, Saccone G, D'Alessandro P, Arduino B, de Placido G, Mascolo M, Insabato L, Zullo F (2019) Significant risk of occult cancer in complex non-atypical endometrial hyperplasia. *Arch Gynecol Obstet* 300(5):1147–1154
25. Travaglino A, Raffone A, Saccone G, Mascolo M, Pignatiello S, Mollo A, de Placido G, Insabato L, Zullo F (2019) PTEN immunohistochemistry in endometrial hyperplasia: which are the optimal criteria for the diagnosis of precancer? *APMIS* 127(4):161–169
26. Travaglino A, Raffone A, Mascolo M, Guida M, Insabato L, Zannoni GF, Zullo F (2019) Clear cell endometrial carcinoma and the TCGA classification. *Histopathology*. 76:336–338. <https://doi.org/10.1111/his.13976>
27. Raffone A, Travaglino A, Saccone G, Insabato L, Mollo A, de Placido G, Zullo F (2019) Endometrial hyperplasia and progression to cancer: which classification system stratifies the risk better? A systematic review and meta-analysis. *Arch Gynecol Obstet* 299(5):1233–1242
28. Raffone A, Travaglino A, Saccone G, D'Alessandro P, Arduino B, Mascolo M, de Placido G, Insabato L, Zullo F (2019) Diabetes mellitus is associated with occult Cancer in endometrial hyperplasia. *Pathol Oncol Res*. <https://doi.org/10.1007/s12253-019-00684-3>
29. Travaglino A, Raffone A, Saccone G, Mollo A, de Placido G, Insabato L, Zullo F (2019) Endometrial hyperplasia and risk of coexistent cancer: WHO vs EIN criteria. *Histopathology* 74(5):676–687
30. Raffone A, Travaglino A, Saccone G, di Maio A, Mollo A, Mascolo M, de Rosa R, de Placido G, Insabato L, Zullo F (2019) Diabetes mellitus and responsiveness of endometrial hyperplasia and early endometrial cancer to conservative treatment. *Gynecol Endocrinol* 35(11):932–937
31. Raffone A, Travaglino A, Saccone G, Cieri M, Mascolo M, Mollo A, Insabato L, Zullo F (2019) Diagnostic and prognostic value of ARID1A in endometrial hyperplasia: a novel marker of occult cancer. *APMIS*. 127:597–606. <https://doi.org/10.1111/apm.12977>
32. Travaglino A, Raffone A, Saccone G et al (2019) Congruence between 1994 WHO classification of endometrial hyperplasia and endometrial intraepithelial neoplasia system. *Am J Clin Pathol* 153(1):40–48
33. Travaglino A, Raffone A, Saccone G, Fuggi M, de Placido G, Mascolo M, Mollo A, Insabato L, Zullo F (2019) Immunophenotype of atypical polypoid adenomyoma of the uterus: diagnostic value and insight on pathogenesis. *Appl Immunohistochem Mol Morphol*. <https://doi.org/10.1097/PAL.0000000000000780>
34. Travaglino A, Raffone A, Saccone G, Mascolo M, D'Alessandro P, Arduino B, Mollo A, Insabato L, Zullo F (2019) Nuclear expression of β -catenin in endometrial hyperplasia as marker of premalignancy. *APMIS*. 127:699–709. <https://doi.org/10.1111/apm.12988>
35. Hoang LN, Ali RH, Lau S, Gilks CB, Lee CH (2014) Immunohistochemical survey of mismatch repair protein expression in uterine sarcomas and carcinosarcomas. *Int J Gynecol Pathol* 33(5):483–491
36. Hembree TN, Teer JK, Hakam A, Chiappori AA (2016) Genetic investigation of uterine carcinosarcoma: case report and cohort analysis. *Cancer Control* 23(1):61–66
37. Zhao S, Bellone S, Lopez S, Thakral D, Schwab C, English DP, Black J, Cocco E, Choi J, Zammataro L, Predolini F, Bonazzoli E, Bi M, Buza N, Hui P, Wong S, Abu-Khalaf M, Ravaggi A, Bignotti E, Bandiera E, Romani C, Todeschini P, Tassi R, Zanotti L, Odicino F, Pecorelli S, Donzelli C, Ardighieri L, Facchetti F, Falchetti M, Silasi DA, Ratner E, Azodi M, Schwartz PE, Mane S, Angioli R, Terranova C, Quick CM, Edraki B, Bilgüvar K, Lee M, Choi M, Stiegler AL, Boggon TJ, Schlessinger J, Lifton RP, Santin AD (2016) Mutational landscape of uterine and ovarian carcinosarcomas implicates histone genes in epithelial-mesenchymal transition. *Proc Natl Acad Sci U S A* 113(43):12238–12243
38. Chen X, Arend R, Hamele-Bena D, Tergas AI, Hawver M, Tong GX, Wright TC, Wright JD (2017) Uterine Carcinosarcomas: clinical, Histopathologic and Immunohistochemical characteristics. *Int J Gynecol Pathol* 36(5):412–419
39. Jones NL, Xiu J, Chatterjee-Paer S, Buckley de Meritens A, Burke WM, Tergas AI, Wright JD, Hou JY (2017) Distinct molecular landscapes between endometrioid and nonendometrioid uterine carcinomas. *Int J Cancer* 140(6):1396–1404

40. Lu X, Zhang L, Zhao H, Chen C, Wang Y, Liu S, Lin X, Wang Y, Zhang Q, Lu T, Yan F (2019) Molecular classification and subtype-specific drug sensitivity research of uterine carcinosarcoma under multi-omics framework. *Cancer Biol Ther* 20(2):227–235
41. Ashley CW, Da Cruz PA, Kumar R et al (2019) Analysis of mutational signatures in primary and metastatic endometrial cancer reveals distinct patterns of DNA repair defects and shifts during tumor progression. *Gynecol Oncol* 152(1):11–19
42. Franceschi T, Durieux E, Morel AP, de Saint Hilaire P, Ray-Coquard I, Puisieux A, Devouassoux-Shisheboran M (2019) Role of epithelial-mesenchymal transition factors in the histogenesis of uterine carcinomas. *Virchows Arch* 475(1):85–94
43. Liu Y, Weber Z, San Lucas FA, Deshpande A, Jakubek YA, Sulaiman R, Fagerness M, Flier N, Sulaiman J, Davis CM, Fowler J, Starks D, Rojas-Español L, Lazar AJ, Davies GE, Ehli EA, Scheet P (2018) Assessing inter-component heterogeneity of biphasic uterine carcinosarcomas. *Gynecol Oncol* 151(2):243–249
44. McConechy MK, Hoang LN, Chui MH et al (2015) In-depth molecular profiling of the biphasic components of uterine carcinosarcomas. *J Pathol Clin Res* 1(3):173–185
45. Cherniack AD, Shen H, Walter V, Stewart C, Murray BA, Bowlby R, Hu X, Ling S, Soslow RA, Broaddus RR, Zuna RE, Robertson G, Laird PW, Kucherlapati R, Mills GB, Weinstein JN, Zhang J, Akbani R, Levine DA, Akbani R, Ally A, Auman JT, Balasundaram M, Balu S, Baylin SB, Beroukhi R, Bodenheimer T, Bogomolny F, Boice L, Bootwalla MS, Bowen J, Bowlby R, Broaddus R, Brooks D, Carlsen R, Cherniack AD, Cho J, Chuah E, Chudamani S, Cibulskis K, Cline M, Dao F, David M, Demchok JA, Dhalla N, Dowdy S, Felau I, Ferguson ML, Frazer S, Frick J, Gabriel S, Gastier-Foster JM, Gehlenborg N, Gerken M, Getz G, Gupta M, Haussler D, Hayes DN, Heiman DI, Hess J, Hoadley KA, Hoffmann R, Holt RA, Hoyle AP, Hu X, Huang M, Hutter CM, Jefferys SR, Jones SJM, Jones CD, Kanchi RS, Kandoth C, Kasaian K, Kerr S, Kim J, Lai PH, Laird PW, Lander E, Lawrence MS, Lee D, Leraas KM, Leshchiner I, Levine DA, Lichtenberg TM, Lin P, Ling S, Liu J, Liu W, Liu Y, Lolla L, Lu Y, Ma Y, Maglinte DT, Marra MA, Mayo M, Meng S, Meyerson M, Mieczkowski PA, Mills GB, Moore RA, Mose LE, Mungall AJ, Mungall K, Murray BA, Naresh R, Noble MS, Olvera N, Parker JS, Perou CM, Perou AH, Pihl T, Radenbaugh AJ, Ramirez NC, Rathmell WK, Roach J, Robertson AG, Sadeghi S, Saksena G, Salvesen HB, Schein JE, Schumacher SE, Shen H, Sheth M, Shi Y, Shih J, Simons JV, Sipahimalani P, Skelly T, Sofia HJ, Soloway MG, Soslow RA, Sougnez C, Stewart C, Sun C, Tam A, Tan D, Tarnuzzer R, Thiessen N, Thorne LB, Tse K, Tseng J, van den Berg DJ, Veluvolu U, Verhaak RGW, Voet D, von Bismarck A, Walter V, Wan Y, Wang Z, Wang C, Weinstein JN, Weisenberger DJ, Wilkerson MD, Winterhoff B, Wise L, Wong T, Wu Y, Yang L, Zenklusen JC, Zhang J(J), Zhang H, Zhang W, Zhu JC, Zmuda E, Zuna RE (2017) Integrated molecular characterization of uterine Carcinosarcoma. *Cancer Cell* 31(3):411–423
46. Le Gallo M, Rudd ML, Urlick ME et al (2018) The FOXA2 transcription factor is frequently somatically mutated in uterine carcinosarcomas and carcinomas. *Cancer* 124(1):65–73
47. Gotoh O, Sugiyama Y, Takazawa Y, Kato K, Tanaka N, Omatsu K, Takeshima N, Nomura H, Hasegawa K, Fujiwara K, Taki M, Matsumura N, Noda T, Mori S (2019) Clinically relevant molecular subtypes and genomic alteration-independent differentiation in gynecologic carcinosarcoma. *Nat Commun* 10(1):4965
48. Prueksaritanond N, Chantape W (2016) Comparative survival outcomes of uterine papillary serous carcinoma, clear cell carcinoma, grade 3 endometrioid adenocarcinoma, and carcinosarcoma of endometrial cancer in Rajavithi Hospital. *J Med Assoc Thai* 99(Suppl 2):S75–S83
49. Zhu J, Wen H, Bi R, Wu X (2016) Clinicopathological characteristics, treatment and outcomes in uterine carcinosarcoma and grade 3 endometrial cancer patients: a comparative study. *J Gynecol Oncol* 27(2):e18
50. Zhang C, Hu W, Jia N, Li Q, Hua K, Tao X, Wang L, Feng W (2015) Uterine carcinosarcoma and high-risk endometrial carcinomas: a clinicopathological comparison. *Int J Gynecol Cancer* 25(4):629–636
51. Altrabulsi B, Malpica A, Deavers MT, Bodurka DC, Broaddus R, Silva EG (2005) Undifferentiated carcinoma of the endometrium. *Am J Surg Pathol* 29(10):1316–1321
52. Taskin OC, Onder S, Topuz S et al (2017) A selected immunohistochemical panel aids in differential diagnosis and prognostic stratification of subtypes of high-grade endometrial carcinoma: a clinicopathologic and immunohistochemical study at a single institution. *Appl Immunohistochem Mol Morphol* 25(10):696–702
53. Stewart CJ, Crook ML (2015) SWI/SNF complex deficiency and mismatch repair protein expression in undifferentiated and dedifferentiated endometrial carcinoma. *Pathology* 47(5):439–445
54. Coatham M, Li X, Karnezis AN, Hoang LN, Tessier-Cloutier B, Meng B, Soslow RA, Blake Gilks C, Huntsman DG, Stewart CJR, Postovit LM, Köbel M, Lee CH (2016) Concurrent ARID1A and ARID1B inactivation in endometrial and ovarian dedifferentiated carcinomas. *Mod Pathol* 29(12):1586–1593
55. Ramalingam P, Croce S, McCluggage WG (2017) Loss of expression of SMARCA4 (BRG1), SMARCA2 (BRM) and SMARCB1 (INI1) in undifferentiated carcinoma of the endometrium is not uncommon and is not always associated with rhabdoid morphology. *Histopathology* 70(3):359–366
56. Rosa-Rosa JM, Leskelä S, Cristóbal-Lana E, Santón A, López-García MÁ, Muñoz G, Pérez-Mies B, Biscuola M, Prat J, Esther OE, Soslow RA, Matias-Guiu X, Palacios J (2016) Molecular genetic heterogeneity in undifferentiated endometrial carcinomas. *Mod Pathol* 29(11):1390–1398
57. Espinosa I, Lee CH, D'Angelo E, Palacios J, Prat J (2017) Undifferentiated and dedifferentiated endometrial carcinomas with POLE exonuclease domain mutations have a favorable prognosis. *Am J Surg Pathol* 41(8):1121–1128
58. Köbel M, Hoang LN, Tessier-Cloutier B, Meng B, Soslow RA, Stewart CJR, Lee CH (2018) Undifferentiated endometrial carcinomas show frequent loss of Core switch/sucrose nonfermentable complex proteins. *Am J Surg Pathol* 42(1):76–83
59. Murali R, Davidson B, Fadare O, Carlson JA, Crum CP, Gilks CB, Irving JA, Malpica A, Matias-Guiu X, McCluggage WG, Mittal K, Oliva E, Parkash V, Rutgers JKL, Staats PN, Stewart CJR, Tornos C, Soslow RA (2019) High-grade endometrial carcinomas: morphologic and Immunohistochemical features, diagnostic challenges and recommendations. *Int J Gynecol Pathol* 38(Suppl 1):S40–S63
60. Stelloo E, Bosse T, Nout RA, MacKay HJ, Church DN, Nijman HW, Leary A, Edmondson RJ, Powell ME, Crosbie EJ, Kitchener HC, Mileskin L, Pollock PM, Smit VT, Creutzberg CL (2015) Refining prognosis and identifying targetable pathways for high-risk endometrial cancer; a TRANSPORTEC initiative. *Mod Pathol* 28(6):836–844
61. Meng B, Hoang LN, McIntyre JB et al (2014) POLE exonuclease domain mutation predicts long progression-free survival in grade 3 endometrioid carcinoma of the endometrium. *Gynecol Oncol* 134(1):15–19
62. Hacking S, Jin C, Komforti M, Liang S, Nasim M (2019) MMR deficient undifferentiated/dedifferentiated endometrial carcinomas showing significant programmed death ligand-1 expression (sp 142) with potential therapeutic implications. *Pathol Res Pract* 22: 152552. <https://doi.org/10.1016/j.prp.2019.152552>