



# Accuracy of One-Step Nucleic Acid Amplification in Detecting Lymph Node Metastases in Endometrial Cancer

Antonio Raffone<sup>1</sup> · Antonio Travaglino<sup>2</sup> · Angela Santoro<sup>3</sup> · Italia Esposito<sup>1</sup> · Giuseppe Angelico<sup>3</sup> · Saveria Spadola<sup>3</sup> · Gian Franco Zannoni<sup>3</sup>

Received: 25 June 2019 / Accepted: 14 August 2019 / Published online: 23 August 2019  
© Arányi Lajos Foundation 2019

## Abstract

One-step nucleic acid amplification (OSNA) is used to intraoperatively detect sentinel lymph node metastases in breast cancer. OSNA has also been proposed in endometrial cancer, but evidence in this regard is unclear to define the diagnostic accuracy of OSNA in detecting lymph node metastases in endometrial cancer. A systematic review and meta-analysis was performed by searching 8 electronic databases from their inception to March 2019 for studies testing the diagnostic accuracy of OSNA in detecting sentinel lymph node metastasis in endometrial cancer. Pathologic ultrastaging was the reference standard. Sensitivity, specificity, positive and negative likelihood ratio (LR+ and LR-), diagnostic odds ratio (DOR) and area under the curve (AUC) on SROC curve were calculated. Four studies with 237 patients and 691 lymph nodes were included. OSNA showed sensitivity = 0.88, specificity = 0.93, LR + = 17.95, LR - = 0.15, DOR = 191.23 and high diagnostic accuracy (AUC = 0.959). OSNA appears as a highly accurate tool for intraoperative assessment of sentinel lymph node in endometrial cancer.

**Keywords** OSNA · Sentinel lymph node · Endometrial cancer · Intraoperative · Ultrastaging · Tailored medicine

## Introduction

Endometrial carcinoma (EC) is the most common gynecologic cancer in developed countries [1–4]. EC is often detected in an early phase, when the tumor is limited to the uterus and lymph nodes are not involved, with a consequent excellent prognosis [5–7].

However, when EC metastasizes to lymph nodes, the 5-years survival rate dramatically decreases from 80 to 90% (FIGO stage I-II) to 51–58% (FIGO stage IIIC) [8]. Therefore, lymph nodes staging is a crucial step in

determining the management of EC, and lymphadenectomy is recommended as standard intervention, except for stage FIGO Ia, low grade EC [9–11]. Nonetheless, lymphadenectomy requires surgical expertise, and it is associated with increased risk of perioperative and postoperative morbidity [12]. For this reason, the possibility of using sentinel lymph node (SLN) examination in EC has received great interest [13–17]. In fact, SLN examination allows the assessment of lymph node staging without the implications related to a wide lymphadenectomy [12]. Furthermore, the SLN examination may be performed intraoperatively, and its status may determine the radicality of the surgery [18]. In particular, The 2018 NCCN Guidelines indicate that SLN mapping may be considered in patients with apparent uterine-confined G1–2 ECs (clinical stage I disease). Moreover, recent evidence suggests that SLN mapping might be used even in high-risk histologies (serous carcinoma, clear cell carcinoma, and carcinosarcoma), although further studies are necessary to define the feasibility of such approach [9].

The optimal approach for SLN mapping appears to be pathologic ultrastaging, based on multiple sections stained with hematoxylin/eosin and immunohistochemistry. Such approach allows an accurate identification of metastases, resulting particularly useful for identifying low-volume

✉ Antonio Raffone  
anton.raffone@gmail.com

<sup>1</sup> Gynecology and Obstetrics Unit, Department of Neurosciences, Reproductive Sciences and Dentistry, School of Medicine, University of Naples Federico II, Via Sergio Pansini, 5, 80131 Naples, Italy

<sup>2</sup> Anatomic Pathology Unit, Department of Advanced Biomedical Sciences, University of Naples Federico II, Naples, Italy

<sup>3</sup> Pathology Unit, Department of Woman and Child Health, Agostino Gemelli University Polyclinic, Catholic University of the Sacred Heart, Rome, Italy

metastases, which constitute approximately half of SLN metastases [19–21]. Unfortunately, ultrastaging takes much time for formalin fixation, paraffin embedment, tissue processing and immunohistochemical stainings, providing a delayed final diagnosis [22]. On the other hand, the intraoperative assessment of frozen sections appears too little sensitive for this purpose [23].

The one-step nucleic acid amplification (OSNA) method, based on Polymerase Chain Reaction (PCR), has been used to detect SLN metastases in breast cancer intraoperatively. OSNA method provides a fast and objective result by quantifying the copies of cytokeratin 19 mRNA in SLN [24–26].

OSNA has also been proposed in endometrial cancer [27], but the feasibility of such approach is still undefined.

In this study, we aimed to assess the diagnostic accuracy of OSNA in detecting SLN metastases in EC, by using pathologic ultrastaging as reference standard.

## Materials and Methods

### Study Protocol

This study followed methods of our previous reviews [28–31].

Methods for search strategy, study selection, data extraction, risk of bias assessment and data analysis were defined a priori. Two authors (AR, GFZ) independently performed all review steps. Disagreements were resolved by consensus among authors.

The study was reported following the Preferred Reporting Item for Systematic Reviews and Meta-analyses (PRISMA) statement [32] and the Synthesizing Evidence from Diagnostic Accuracy Tests (SEDATe) guideline [33].

### Search Strategy

MEDLINE, Scopus, EMBASE, OVID, Web of Sciences, [ClinicalTrials.gov](http://ClinicalTrials.gov), Cochrane Library and Google Scholar were used as electronic databases. Several researches were conducted by following different combinations of the following text words: “endometri\*”; “cancer”; “carcinoma”; “lymph node\*”; “sentinel”; “metasta\*”; “on site”; “OSNA”; “cytokeratin 19”; “CK 19”, from the inception of each database to March 2019. References from relevant articles were also assessed for further eligible studies.

### Study Selection

All peer-reviewed studies assessing lymph nodes from EC patients by using OSNA were included in the systematic review. Data not extractable, overlapping patient data, case reports and reviews were defined a priori as exclusion criteria. No language restrictions were planned.

### Data Extraction

Data extraction followed methods of previous diagnostic accuracy studies [34–38].

Original data from each study were not modified during extraction. OSNA was considered as the index test. A threshold of 250 copies of cytokeratin 19 mRNA by  $\mu\text{l}$  was used to differentiate between negative test (mRNA copies  $<250/\mu\text{l}$ ) and positive test (mRNA copies  $\geq 250/\mu\text{l}$ ). Histologic examination with ultrastaging (multiple histologic sections of lymph node plus immunohistochemical analysis) was considered as the reference standard. Two-by-two contingency table was prepared for each study, reporting true positives (OSNA+, histology+), false positives (OSNA+, histology-), false negatives (OSNA-, histology+) and true negatives (OSNA-, histology-).

### Assessment of Risk of Bias within Studies

The revised Quality Assessment of Diagnostic Accuracy Studies (QUADAS-2) [39] were used to assess the risk of bias within studies. Four domains were evaluated: 1) Patient selection (i.e. if the patients were consecutively selected); 2) Index test (i.e. if methods for OSNA were unbiased); 3) Reference standard (i.e. if lymph node histologic assessment was correctly performed); 4) Flow and Timing (i.e. if all specimens were assessed with both the same index and the same reference standard). Authors' judgments were categorized as “low risk,” “unclear risk” or “high risk of bias.”

Concerns about applicability were also evaluated for the domains 1, 2 and 3 (i.e. if the study methods did not fit the objective of our review, regardless of their correctness).

### Data Analysis

Sensitivity, specificity, positive likelihood ratio (LR+), negative likelihood ratio (LR-) and diagnostic odds ratio (DOR) with 95% confidence interval (CI) were calculated for each study and as pooled estimates and reported graphically on forest plots. Statistical heterogeneity among studies was quantified by using the inconsistency index ( $I^2$ ): heterogeneity was categorized as null ( $I^2 = 0\%$ ), minimal ( $0\% < I^2 < 25\%$ ), low ( $25 \leq I^2 < 50\%$ ), moderate ( $50 \leq I^2 < 75\%$ ) or high ( $I^2 \geq 75\%$ ), as previously described [40, 41]. A random effect model was used to pool data, as recommended by the SEDATe guidelines, since an actual heterogeneity is expected in meta-analyses of diagnostic accuracy [33].

Area under the curve (AUC) was calculated on summary receiver operating characteristic (SROC) curves. The diagnostic accuracy of OSNA was categorized as follows: absent for  $AUC \leq 0.5$ , low for  $0.5 < AUC \leq 0.75$ , moderate for  $0.75 < AUC \leq 0.9$ , high for  $0.9 < AUC \leq 0.97$ , very high for  $AUC >$

0.97. LR+, LR- and DOR were interpreted as previously described [59, 60]

The data analysis was performed using Meta-DiSc version 1.4 (Clinical Biostatistics Unit, Ramon y Cajal Hospital, Madrid, Spain) and Review Manager 5.3 (Copenhagen: The Nordic Cochrane Centre, Cochrane Collaboration, 2014).

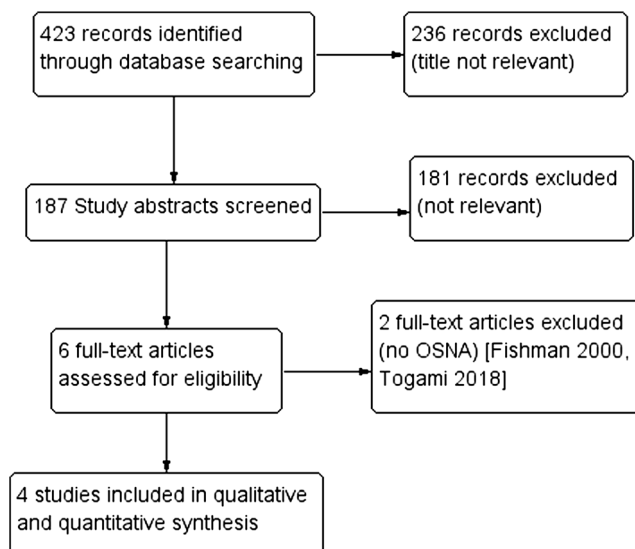
## Results

### Selection and Characteristics of the Studies

Four studies were included in the systematic review [22, 27, 42, 43]. Two other studies that used PCR for detecting SLN metastases were excluded, because they did not adopt OSNA [44, 45]; furthermore, one of them used CK 20 instead of CK19 [44], while the other one assessed only macrometastases [45]. The whole process of study selection for the database PubMed is presented in Fig. 1.

Overall, 691 lymph nodes from 237 endometrial cancer patients were assessed. Histologic diagnoses included 202 endometrioid carcinomas, 21 clear cell or serous carcinomas, 6 carcinosarcomas, 4 mixed carcinomas, 2 adenosquamous carcinomas and 2 undifferentiated carcinomas. SLNs were identified by injecting indocyanine green or blue dye intracervically. Intraoperatively, each SLN was sectioned, and part of SLN underwent OSNA assay, while the remaining part underwent histologic examination with ultrastaging.

Characteristics of the included studies are reported in Table 1.



**Fig. 1** Flow diagram of studies identified in the systematic review (Prisma template [Preferred Reporting Item for Systematic Reviews and Meta-analyses])

### Risk of Bias within Studies Assessment

For the “patient selection” domain, one study was considered at low risk of bias due to the inclusion of consecutive patients, while in the other 3 studies it was unclear whether patients were consecutive [22, 27, 42].

For the “index test” domain, all studies were considered at low risk of bias, since all used at least half of SLN for OSNA analysis; moreover, all studies considered 250 copies of cytokeratin 19 by  $\mu\text{l}$  as criterion for positivity, which has been shown to be the most accurate threshold [27].

For the “reference standard” domain, 3 studies were considered at low risk, since they performed multiple histologic sections and immunohistochemical staining to detect lymph node metastases; the other study was considered at unclear risk, because it did not report whether immunohistochemistry was used for ultrastaging [27].

For the “flow and timing” domain, all studies were considered at low risk, since all SLN underwent both the same index and the same reference standard.

No concerns about applicability were raised. Authors’ judgements about the risk of bias are shown in Fig. 2.

### Diagnostic Accuracy Analysis

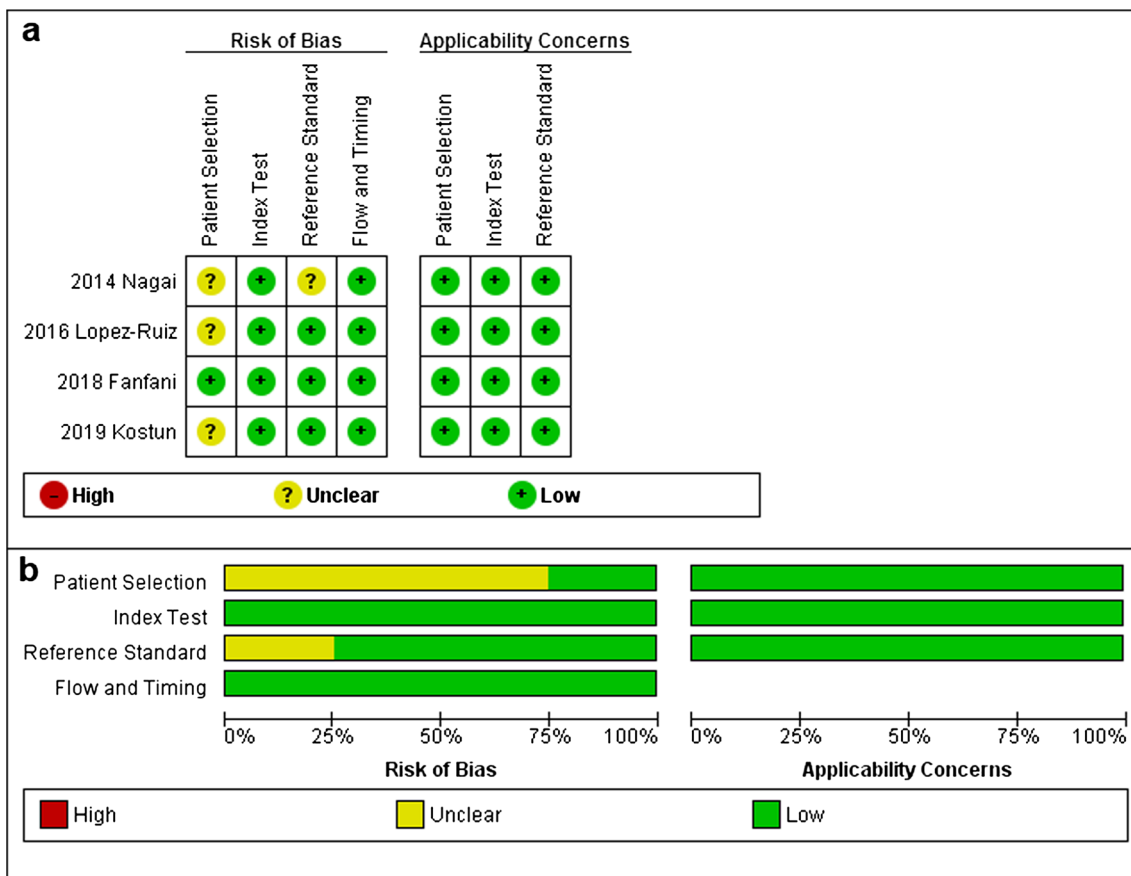
Pooled sensitivity and specificity of OSNA in detecting lymph node metastases were 0.88 (95% CI 0.74–0.96) and 0.93 (95% CI, 0.90–0.95) respectively, with a pooled LR+ and a LR- of 17.95 (95% CI 4.72–68.33) and 0.15 (95% CI 0.07–0.32) respectively. Pooled DOR was 191.23 (95% CI 46.95–778.78). The heterogeneity was null for sensitivity and LR- ( $I^2 = 0\%$ ), minimal for DOR ( $I^2 = 15.6\%$ ) and high for specificity ( $I^2 = 92\%$ ) and LR+ ( $I^2 = 87.5\%$ ) (Fig. 3).

SROC curves analysis showed high diagnostic accuracy (AUC = 0.959) (Fig. 4).

### Discussion

According to our results, OSNA appears a highly accurate method to detect metastases in SLN in EC. To our knowledge, this is the first meta-analysis assessing the diagnostic accuracy of OSNA method in EC.

The use of SNL mapping in EC has been giving more and more interest given the clear advantages for patients and surgeons [12–18]. In fact, pelvic and/or paraaortic lymphadenectomy is a procedure which require time and surgical technique, and may cause perioperative morbidity and lower arts lymphedema in a considerable percentage of cases [12, 22]. On the other hand, not assessing lymph nodes entails a risk of understaging and undertreatment [18, 46]. In this background, SLN assessment appears as a good compromise [9, 10].



**Fig. 2** **a** Assessment of risk of bias. Summary of risk of bias for each study; Plus sign: low risk of bias; minus sign: high risk of bias; question mark: unclear risk of bias. **b** Risk of bias graph about each risk of bias item presented as percentages across all included studies

Over time, some uncertainties regarding methods for SLN mapping in EC have been resolved, in particular regarding the type of dye to be used and the optimal site of injection. In fact, several studies have shown superiority of indocyanine green over methylene blue in identifying SLN [47], and uterine cervix seems to be a reliable injection site [48]. To date,

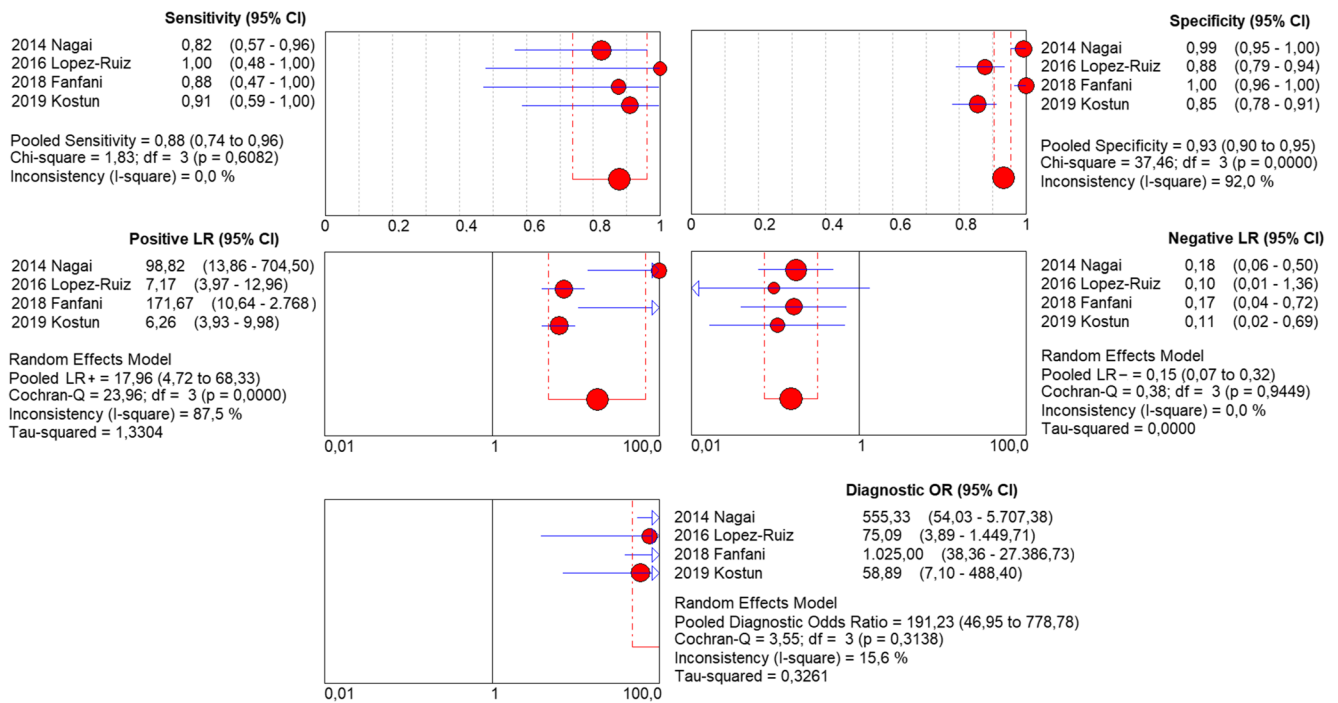
SLN mapping for EC is still experimental, but even guidelines recognize the increasing evidence about its usefulness [9, 10].

The use of frozen section is widespread and is necessary to perform an intraoperative histologic examination of SLN. In fact, frozen sections allow avoiding the time required for the standard processing of pathologic tissues [49]. Nonetheless,

**Table 1** Characteristics of the included studies

Study	Country	Institution	Period of enrollment	Patient number	Histology	Lymph nodes number
2014 Nagai	Japan	Tohoku University, Sendai	2009–2012*	70*	60 EC, 4 CC/SC, 3 MC, 1 ASC, 2 CS*	215*
			2010–2012	35	30 EC, 3 CC/SC, 1 ASC, 1 CS	137
2016 Lopez-Ruiz	Spain	University Hospital La Paz, Madrid	2014–2015	34	25 EC, 5 SC, 2 CS, 1 UC, 1 MC	94
2018 Fanfani	Italy	Catholic University of the Sacred Heart, Rome	2016	40	33 EC, 4 SC, 2 CC, 1 UC	110
2019 Kostun	Czech Republic	Charles University, Prague	2016–2018	58	54 EC, 2 CC, 1 SC, 1 CS	135
TOT			2009–2018	237	202 EC, 21 CC/SC, 6 CS, 4 MC, 2 ASC, 2 UC	691

\*: Data regarding a test set of lymph nodes (not only sentinel) assessed to define the optimal threshold of cytokeratin 19 mRNA copies/ $\mu$ l



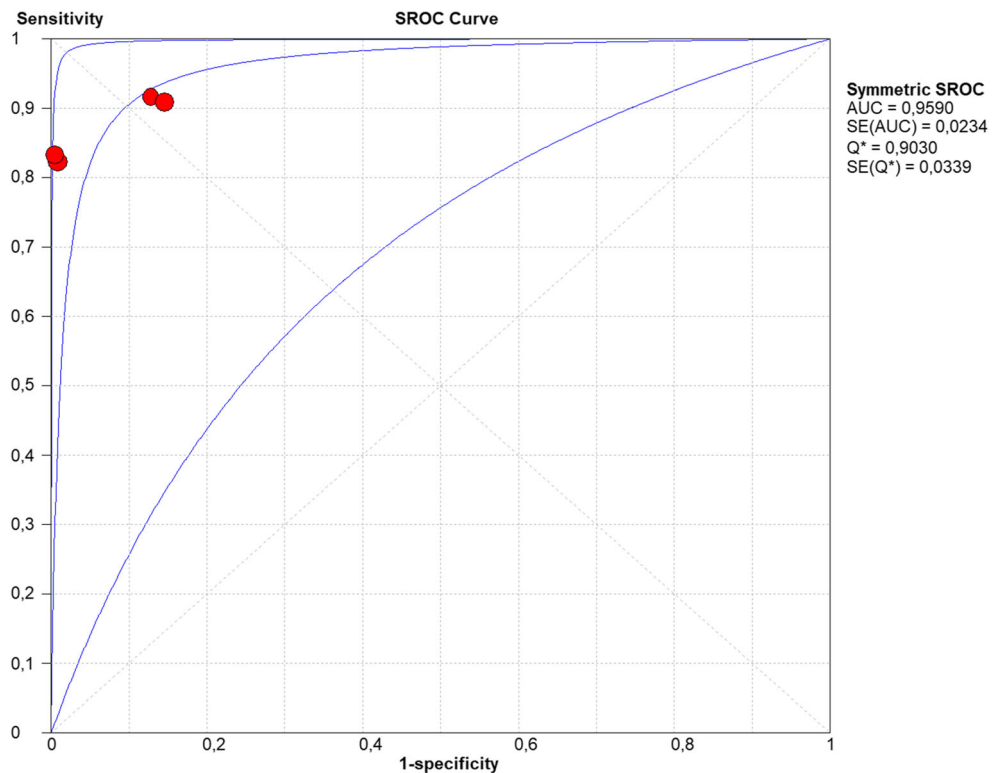
**Fig. 3** Sensitivity, specificity, positive and negative likelihood ratios (LR+ and LR-) and diagnostic odds ratio (DOR) of OSNA assay in detecting sentinel lymph node metastases in endometrial cancer

histologic diagnosis performed on frozen section may be little accurate, with a sensitivity as low as 0.50 [43]. Furthermore, frozen sections examination cannot be supported by ancillary techniques such as immunohistochemistry. On the other hand, pathologic ultrastaging, which is the gold standard, cannot be

performed intraoperatively [19, 20] and no universal protocol for SLN ultrastaging has been defined [50].

As showed in breast cancer, the OSNA method may overcome these issues [24–26, 51]. Indeed, OSNA might be as fast as frozen section and as accurate as pathologic ultrastaging,

**Fig. 4** Area under the curve (AUC) calculated on summary receiver operating characteristic (SROC) curve for the diagnostic accuracy of OSNA assay in detecting sentinel lymph node metastases in endometrial cancer



eliminating subjectivity from the diagnosis. Our results appear to confirm the reliability of OSNA, showing a high accuracy in detecting metastases (AUC = 0.96). Such accuracy appears adequate to support the use of OSNA for EC. These results are strengthened by the consistency in the methods among the included studies. In fact, in all studies, every SLN underwent both OSNA (with the same threshold of 250 CK 19 mRNA copies/ $\mu$ l) and pathologic ultrastaging (which is regarded as the gold standard).

Interestingly, despite the high accuracy found, a small discrepancy still existed between OSNA results and ultrastaging results. It would be interesting to assess the causes for such a discordance. It cannot be excluded that variations in sensitivity and specificity may derive from the sampling method of SLN. Indeed, in order to assess each SLN with both OSNA and pathologic ultrastaging, part of the lymph node was used for the former, and another part for the latter. Thus, it is possible that small metastases were present only in the sections that underwent pathologic ultrastaging, and not in those used for OSNA, or vice versa. Another cause for the non-perfect specificity may lie in the possibility of benign epithelial inclusions within SLN, which has been described in the literature [22].

Limitations of OSNA are the impossibility of assessing the morphologic features of the metastasis (e.g. focal or diffuse lymph node involvement, extranodal involvement) and the possible low reliability in some histotypes, such as carcinosarcoma, undifferentiated carcinoma and dedifferentiated carcinoma, in which a loss of CK 19 expression might be hypothesized. To date, these limitations should not affect the clinical value of OSNA, since the current staging system does not consider the morphologic features of metastasis, and the current guidelines do not recommend SLN mapping in high-risk histologies [9, 52].

An argument against the use of OSNA may be its cost, which is high if compared to frozen section and even to pathologic ultrastaging (about 10 times more expensive). However, it has been suggested that these additional costs may be widely recouped by reducing costs of inadequate treatments. In fact, in breast cancer the cost/benefit ratio seems to clearly favor the use of OSNA [22, 53, 54].

Moreover, OSNA is also able to discriminate lymph node metastases according to their volume. In fact, a number of CK mRNA copies ranging from 250 to 4999/ $\mu$ l is considered indicative for a micrometastasis, while a value of 5000/ $\mu$ l or more is considered indicative for a macrometastasis [22, 27, 42, 43]. The prognostic significance of micrometastases and isolated tumor cells is still undefined. In fact, some authors suggested that the prognostic value of lymph node metastases may depend on their volume [55–57]. This idea is well accepted in breast cancer, where the staging system include the size of lymph node metastases [58]. Similarly, the 8th edition of the AJCC Staging Manual incorporates pN0 (i+) and pN1mi

sub-categories for lymph node metastases in EC [52]. In this regard, OSNA might also allow an accurate risk stratification for a more tailored management. Further studies are necessary in this field.

## Conclusion

OSNA appears as a quick, objective and reliable method to intraoperatively detect SLN metastases in endometrial cancer. Its high accuracy may support its introduction in the common practice.

## Compliance with Ethical Standards

**Conflict of Interest** The authors report no conflict of interest.

## References

1. Globocan, Northern America, WHO Europe Region (EURO). Estimated cancer incidence, all ages: female. 2012. Accessed January 23, 2017
2. Travaglino A, Raffone A, Saccone G, Insabato L, Mollo A, de Placido G, Zullo F (2018) PTEN as a predictive marker of response to conservative treatment in endometrial hyperplasia and early endometrial cancer. A systematic review and meta-analysis. *Eur J Obstet Gynecol Reprod Biol* 231:104–110
3. Travaglino A, Raffone A, Saccone G, de Luca C, Mollo A, Mascolo M, de Placido G, Insabato L, Zullo F (2019) Immunohistochemical nuclear expression of  $\beta$ -catenin as a surrogate of CTNNB1 exon 3 mutation in endometrial Cancer. *Am J Clin Pathol* 151(5):529–538
4. Travaglino A, Raffone A, Saccone G, Insabato L, Mollo A, de Placido G, Zullo F (2019) Immunohistochemical predictive markers of response to conservative treatment of endometrial hyperplasia and early endometrial cancer: a systematic review. *Acta Obstet Gynecol Scand*. <https://doi.org/10.1111/aogs.13587> [Epub ahead of print]
5. Giampaolino P, Di Spiezio SA, Mollo A et al (2019) Hysteroscopic Endometrial Focal Resection followed by Levonorgestrel Intrauterine Device Insertion as a Fertility-Sparing Treatment of Atypical Endometrial Hyperplasia and Early Endometrial Cancer: A Retrospective Study. *J Minim Invasive Gynecol* 26(4):648–656
6. Creasman W (2009) Revised FIGO staging for carcinoma of the endometrium. *Int J Gynaecol Obstet* 105(2):109–109
7. Raffone A, Travaglino A, Saccone G, Mollo A, de Placido G, Insabato L, Zullo F (2019) Should progesterone and estrogens receptors be assessed for predicting the response to conservative treatment of endometrial hyperplasia and cancer? A systematic review and meta-analysis. *Acta Obstet Gynecol Scand* 98:976–987. <https://doi.org/10.1111/aogs.13586>. [Epub ahead of print]
8. Lewin SN, Wright JD (2011) Comparative performance of the 2009 international federation of gynecology and obstetrics' staging system for uterine corpus cancer. *Obstet Gynecol* 117(5):1226
9. National Comprehensive Cancer Network (NCCN). NCCN Clinical Practice Guidelines in Oncology. NCCN Guidelines Version 2.2018 Uterine Neoplasms
10. Colombo N, Creutzberg C, Amant F, Bosse T, González-Martín A, Ledermann J, Marth C, Nout R, Querleu D, Mirza MR, Sessa C, ESMO-ESGO-ESTRO Endometrial Consensus Conference Working Group (2016) ESMO-ESGO-ESTRO consensus

- conference on endometrial Cancer: diagnosis, treatment and follow-up. *Int J Gynecol Cancer* 26(1):2–30
11. Kitchener H, Swart AM, Qian Q, Amos C, Parmar MK (2009) Efficacy of systematic pelvic lymphadenectomy in endometrial cancer (MRC ASTEC trial): a randomised study. *Lancet* (London, England) 373(9658):125–136
  12. Chambers LM, Vargas R, Michener CM (2019) Sentinel lymph node mapping in endometrial and cervical cancer: a survey of practices and attitudes in gynecologic oncologists. *J Gynecol Oncol* 30(3):e35
  13. Lin H, Ding Z, Kota VG, Zhang X, Zhou J (2017) Sentinel lymph node mapping in endometrial cancer: a systematic review and meta-analysis. *Oncotarget*. 8(28):46601–46610
  14. Bodurtha Smith AJ, Fader AN, Tanner EJ (2017) Sentinel lymph node assessment in endometrial cancer: a systematic review and meta-analysis. *Am J Obstet Gynecol* 216(5):459–476.e10
  15. Ruscito I, Gasparri ML, Braicu EI, Bellati F, Raio L, Sehouli J, Mueller MD, Panici PB, Papadia A (2016) Sentinel node mapping in cervical and endometrial Cancer: Indocyanine green versus other conventional dyes-a meta-analysis. *Ann Surg Oncol* 23(11):3749–3756
  16. Ansari M, Rad MA, Hassanzadeh M, Gholami H, Yousefi Z, Dabbagh VR, Sadeghi R (2013) Sentinel node biopsy in endometrial cancer: systematic review and meta-analysis of the literature. *Eur J Gynaecol Oncol* 34(5):387–401
  17. How JA, O'Farrell P, Amajoud Z, Lau S, Salvador S, How E, Gotlieb WH (2018) Sentinel lymph node mapping in endometrial cancer: a systematic review and meta-analysis. *Minerva Ginecol* 70(2):194–214
  18. Daraï E, Dubernard G, Bats AS, Heitz D, Mathevet P, Marret H, Querleu D, Golfier F, Leblanc E, Rouzier R, Ballester M (2015) Sentinel node biopsy for the management of early stage endometrial cancer: long-term results of the SENTI-ENDO study. *Gynecol Oncol* 136(1):54–59
  19. Bézu C, Coutant C, Ballester M, Feron JG, Rouzier R, Uzan S, Daraï E (2010) Ultrastaging of lymph node in uterine cancers. *J Exp Clin Cancer Res* 29:5
  20. Torné A, Puig-Tintoré LM (2004) The use of sentinel lymph nodes in gynaecological malignancies. *Curr Opin Obstet Gynecol* 16(1):57–64
  21. Holloway RW, Abu-Rustum NR, Backes FJ, Boggess JF, Gotlieb WH, Jeffrey Lowery W, Rossi EC, Tanner EJ, Wolsky RJ (2017) Sentinel lymph node mapping and staging in endometrial Cancer: a Society of Gynecologic Oncology Literature Review with consensus recommendations. *Gynecol Oncol* 146(2):405–415
  22. Kost'un J, Pešta M, Sláma J, Slunéčko R, Vlasák P, Bouda J, Novotný Z, Topolčán O, Kučera R, Kulda V, Houfková K, Berezovskiy D, Bartáková A, Presl J (2019) One-step nucleic acid amplification vs ultrastaging in the detection of sentinel lymph node metastasis in endometrial cancer patients. *J Surg Oncol* 119(3):361–369
  23. Slama J, Dunder P, Dusek L, Cibula D (2013) High false negative rate of frozen section examination of sentinel lymph nodes in patients with cervical cancer. *Gynecol Oncol* 129(2):384–388
  24. Zhou M, Wang X, Jiang L, Chen X, Bao X, Chen X (2018) The diagnostic value of one step nucleic acid amplification (OSNA) in differentiating lymph node metastasis of tumors: a systematic review and meta-analysis. *Int J Surg* 56:49–56
  25. Shi F, Liang Z, Zhang Q, Wang C, Liu X (2018) The performance of one-step nucleic acid amplification assay for intraoperative detection of sentinel lymph node macrometastasis in breast cancer: an updated meta-analysis. *Breast*. 39:39–45
  26. Shi F, Zhang Q, Liang Z, Zhang M, Liu X (2017) One-step nucleic acid amplification assay is an accurate technique for sentinel lymph node biopsy of breast cancer patients: a meta-analysis. *Br J Cancer* 117(8):1185–1191
  27. Nagai T, Niikura H, Okamoto S, Nakabayashi K, Matoda M, Utsunomiya H, Nagase S, Watanabe M, Takeshima N, Yaegashi N (2015) A new diagnostic method for rapid detection of lymph node metastases using a one-step nucleic acid amplification (OSNA) assay in endometrial cancer. *Ann Surg Oncol* 22(3):980–986
  28. Raffone A, Travaglini A, Saccone G, Insabato L, Mollo A, de Placido G, Zullo F (2019) Endometrial hyperplasia and progression to cancer: which classification system stratifies the risk better? A systematic review and meta-analysis. *Arch Gynecol Obstet* 299(5):1233–1242
  29. Raffone A, Travaglini A, Saccone G, Viggiani M, Giampaolino P, Insabato L, Mollo A, de Placido G, Zullo F (2019) PTEN expression in endometrial hyperplasia and risk of cancer: a systematic review and meta-analysis. *Arch Gynecol Obstet* 299(6):1511–1524
  30. Travaglini A, Raffone A, Saccone G, Mollo A, de Placido G, Mascolo M, Insabato L, Zullo F (2019) Complexity of glandular architecture should be reconsidered in the classification and management of endometrial hyperplasia. *APMIS*. 127(6):427–434
  31. Raffone A, Travaglini A, Saccone G, Alviggi C, Mascolo M, de Placido G, Insabato L, Mollo A, Zullo F (2019) Management of women with atypical polypoid adenomyoma of the uterus: a quantitative systematic review. *Acta Obstet Gynecol Scand* 98(7):842–855
  32. Moher D, Shamseer L, Clarke M et al (2015) Preferred reporting items for systematic review and meta-analysis protocols (PRISMA-P) 2015 statement. *Syst Rev* 4:1
  33. Sotiriadis A, Papatheodorou SI, Martins WP (2016) Synthesizing evidence from diagnostic accuracy tests: the SEDATE guideline. *Ultrasound Obstet Gynecol* 47(3):386–395
  34. Travaglini A, Raffone A, Saccone G, Insabato L, Mollo A, de Placido G, Zullo F (2018) Loss of B-cell lymphoma 2 immunohistochemical expression in endometrial hyperplasia: a specific marker of precancer and novel indication for treatment: a systematic review and meta-analysis. *Acta Obstet Gynecol Scand* 97(12):1415–1426
  35. Travaglini A, Raffone A, Saccone G, Mollo A, de Placido G, Insabato L, Zullo F (2019) Endometrial hyperplasia and risk of coexistent cancer: WHO vs EIN criteria. *Histopathology* 74(5):676–687
  36. Raffone A, Travaglini A, Saccone G, Mascolo M, Insabato L, Mollo A, de Placido G, Zullo F (2019) PAX2 in endometrial carcinogenesis and in differential diagnosis of endometrial hyperplasia. A systematic review and meta-analysis of diagnostic accuracy. *Acta Obstet Gynecol Scand* 98(3):287–299
  37. Raffone A, Travaglini A, Saccone G, Campanino MR, Mollo A, de Placido G, Insabato L, Zullo F (2019) Loss of PTEN expression as diagnostic marker of endometrial precancer: a systematic review and meta-analysis. *Acta Obstet Gynecol Scand* 98(3):275–286
  38. Travaglini A, Raffone A, Saccone G, Mascolo M, Pignatiello S, Mollo A, de Placido G, Insabato L, Zullo F (2019) PTEN immunohistochemistry in endometrial hyperplasia: which are the optimal criteria for the diagnosis of precancer? *APMIS* 127(4):161–169
  39. Whiting PF, Rutjes AW, Westwood ME, Mallett S, Deeks JJ, Reitsma JB, Leeflang MM, Sterne JA, Bossuyt PM, QUADAS-2 Group (2011) QUADAS-2: a revised tool for the quality assessment of diagnostic accuracy studies. *Ann Intern Med* 155(8):529–536
  40. Raffone A, Travaglini A, Saccone G, di Maio A, Mollo A, Mascolo M, de Rosa R, de Placido G, Insabato L, Zullo F (2019) Diabetes mellitus and responsiveness of endometrial hyperplasia and early endometrial cancer to conservative treatment. *Gynecol Endocrinol* 5:1–6. <https://doi.org/10.1080/09513590.2019.1624716> [Epub ahead of print]
  41. Raffone A, Travaglini A, Saccone G, D'Alessandro P, Arduino B, Mascolo M, de Placido G, Insabato L, Zullo F (2019) Diabetes mellitus is associated with occult Cancer in endometrial

- hyperplasia. *Pathol Oncol Res.* <https://doi.org/10.1007/s12253-019-00684-3> [Epub ahead of print] Review
42. López-Ruiz ME, Diestro MD, Yébenes L, Berjón A, Díaz de la Noval B, Mendiola M, de Santiago J, Hardisson D (2016) One-step nucleic acid amplification (OSNA) for the detection of sentinel lymph node metastasis in endometrial cancer. *Gynecol Oncol* 143(1):54–59
  43. Fanfani F, Monterossi G, Ghizzoni V, Rossi ED, Dinoi G, Inzani F, Fagotti A, Gueli Alletti S, Scarpellini F, Nero C, Santoro A, Scambia G, Zannoni GF (2018) One-step nucleic acid amplification (OSNA): a fast molecular test based on CK19 mRNA concentration for assessment of lymph-nodes metastases in early stage endometrial cancer. *PLoS One* 13(4):e0195877
  44. Fishman A, Klein A, Zemer R, Zimlichman S, Bernheim J, Cohen I, Altaras MM (2000) Detection of micrometastasis by cytokeratin-20 (reverse transcription polymerase chain reaction) in lymph nodes of patients with endometrial cancer. *Gynecol Oncol* 77(3):399–404
  45. Togami S, Kawamura T, Fukuda M, Yanazume S, Kamio M, Kobayashi H (2019) Quantitative RT-PCR assay for detecting lymph node metastasis in endometrial Cancer: a preliminary study. *Oncology* 96(4):179–182
  46. Ballester M, Naoura I, Chéreau E, Seror J, Bats AS, Bricou A, Daraï E (2013) Sentinel node biopsy upstages patients with presumed low- and intermediate-risk endometrial cancer: results of a multicenter study. *Ann Surg Oncol* 20(2):407–412
  47. Rozenholc A, Samouelian V, Warkus T et al (2019) Green versus blue: Randomized controlled trial comparing indocyanine green with methylene blue for sentinel lymph node detection in endometrial cancer. *Gynecol Oncol.* <https://doi.org/10.1016/j.ygyno.2019.03.103> pii: S0090–8258(19)30296–3. [Epub ahead of print]
  48. Rossi EC (2019) Current state of sentinel lymph nodes for women with endometrial cancer. *Int J Gynecol Cancer* 29(3):613–621
  49. Liu LC, Lang JE, Lu Y, Roe D, Hwang SE, Ewing CA, Esserman LJ, Morita E, Treseler P, Leong SP (2011) Intraoperative frozen section analysis of sentinel lymph nodes in breast cancer patients: a meta-analysis and single-institution experience. *Cancer.* 117(2): 250–258
  50. Silveberg SG (2007) The endometrium. *Arch Pathol Lab Med* 131: 372–382
  51. Tamaki Y (2017) One-step nucleic acid amplification (OSNA): where do we go with it? *Int J Clin Oncol* 22(1):3–10
  52. American Joint Committee on Cancer (AJCC) *Cancer Staging Atlas.* NY: Springer, 2017. 8th edition
  53. Raia-Barjat T, Trombert B, Khaddage A, Douchet C, Seffert P, Peoc'h M, Falk AT, Magné N, Chaleur C (2014) OSNA (one-step nucleic acid amplification) sentinel lymph node intraoperative molecular analysis in breast cancer: a cost-benefit analysis. *Med Oncol* 31(12):322
  54. Guillén-Paredes MP, Carrasco-González L, Cháves-Benito A, Campillo-Soto Á, Carrillo A, Aguayo-Albasini JL (2011) One-step nucleic acid amplification (OSNA) assay for sentinel lymph node metastases as an alternative to conventional postoperative histology in breast cancer: a cost-benefit analysis. *Cir Esp* 89(7): 456–462
  55. Bogani G, Mariani A, Paolini B et al (2019) Low-volume disease in endometrial cancer: The role of micrometastasis and isolated tumor cells. *Gynecol Oncol.* <https://doi.org/10.1016/j.ygyno.2019.02.027> pii: S0090–8258(19)30137–4. [Epub ahead of print]
  56. Plante M, Stanleigh J, Renaud MC, Sebastianelli A, Grondin K, Grégoire J (2017) Isolated tumor cells identified by sentinel lymph node mapping in endometrial cancer: does adjuvant treatment matter? *Gynecol Oncol* 146(2):240–246
  57. St Clair CM, Eriksson AG, Ducie JA et al (2016) Low-volume lymph node metastasis discovered during sentinel lymph node mapping for endometrial carcinoma. *Ann Surg Oncol* 23(5): 1653–1659
  58. Tvedskov TF (2012) Staging of women with breast cancer after introduction of sentinel node guided axillary dissection. *Dan Med J* 59(7):B4475
  59. Raffone A, Travaglino A, Saccone G, Cieri M, Mascolo M, Mollo A, Insabato L, Zullo F (2019) Diagnostic and prognostic value of ARID1A in endometrial hyperplasia: a novel marker of occult cancer. *APMIS* 127(9):597–606
  60. Travaglino A, Raffone A, Saccone G, Mascolo M, D'Alessandro P, Arduino B, Mollo A, Insabato L, Zullo F (2019) Nuclear expression of  $\beta$ -catenin in endometrial hyperplasia as marker of premalignancy. *APMIS.*

**Publisher's Note** Springer Nature remains neutral with regard to jurisdictional claims in published maps and institutional affiliations.