

## CASE REPORT

## Malignant Struma Ovarii

Fevziye KABUKCUOGLU, Alparslan BAKSU, Banu YILMAZ, Alpay AKTUMEN, Ismail EVREN

• İli Etfal Training and Research Hospital, Pathology Department, Istanbul, Turkey

**Malignant struma ovarii is a rare form of ovarian germ cell tumors. Because of its rarity, diagnosis and management of the tumor has not been clearly defined. A 52-year-old female with follicular variant of papillary carcinoma arising in struma ovarii is presented. There was no evidence of clinical malignancy or metastases. However on the basis of histopathologic findings, the case was diagnosed as**

**Keywords:** Ovary, malignant struma ovarii, germ cell tumor

**It was accepted as stage Ia tumor and no other treatment was considered after radical excision. Due to its fairly good prognosis, surgical excision has been the preferred treatment for those who do not have disseminated disease. Nevertheless, long-term follow-up is necessary to determine the course of the disease**(Pathology Oncology Research Vol 8, No 2, 145–147, 2002)

### Introduction

Germ cell tumors constitute 15-20% of ovarian tumors and the majority of them are mature cystic teratomas.<sup>12</sup> While 5-15% of teratomas contain small foci of thyroid tissue, struma ovarii is diagnosed when thyroid tissue is the predominant element.<sup>3,4,9,12</sup> Approximately 5% of struma ovarii show malignant transformation.<sup>9</sup> Due to its rarity, there has been some controversy about the diagnosis and treatment, and prognosis is difficult to evaluate.

A case of malignant struma ovarii, with a review of the literature including diagnostic and treatment guidelines, is presented in this study

### Case report

The patient was a 52-year-old female. She was admitted to the hospital for evaluation of polymenorrhea. Physical examination and pelvic ultrasonography of the patient revealed a mobile, semisolid mass in the right ovarian region. Pelvic MRI examination showed a mass with irregular contours measuring 7x6x4.5 cm at the right paracentral part of the posterior uterus. Post contrast examination showed a heterogeneous mass with small cystic areas.

Peripheral invasion or enlargement of pelvic lymph nodes was not demonstrated. Her routine blood and urine tests were within normal limits. Tumor markers were normal. HCG: 0.8 IU/l,  $\beta$ HCG: 1 IU/l, CEA: 0.63 ng/ml, CA125: 9.3  $\mu$ g/ml, CA15-3: 20  $\mu$ g/ml, CA19-9: 3.00  $\mu$ g/ml, AFP<0.50 IU/ml. Cervical smear examination showed no cytological atypia. Pathologic examination of the endometrial curettage material was consistent with late proliferative phase endometrium. Laparotomy was performed. Pelvic and abdominal washings were obtained. uterus was retrovert, mobile and normal sized. The left ovary and the fallopian tube were normal. Right salpingo-oophorectomy material was sent for frozen section and was reported to be malignant. Due to the age of the patient, conservative surgery was not considered. total abdominal hysterectomy, left salpingo-oophorectomy, bilateral pelvic and paraaortic lymph node dissection, omentectomy and appendectomy were performed.

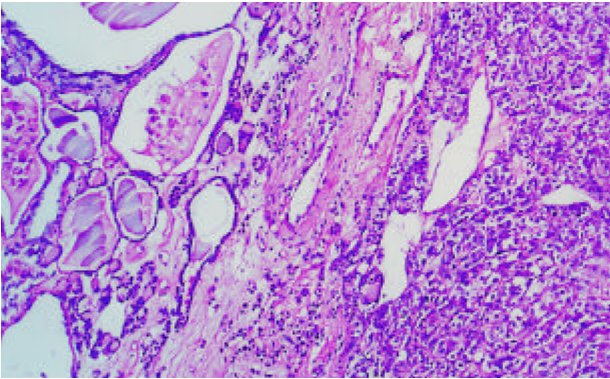
Pathologic examination: the right salpingo-oophorectomy specimen consisted of an encapsulated mass measuring 6x5x4 cm with a 4.5 cm long tube over it. Almost half of the cut surface was gelatinous glossy yellow reminiscent of struma ovarii. The remaining part of the mass was dull grey-yellow and more solid in consistency. Clearly demarcated ovarian tissue measuring 3x2x1.5 cm was identified next to the gelatinous areas. The hysterectomy material contained 2.5x2.0x1.5 cm left ovary. Nabothian cysts were seen on the cervix. The endometrium was 0.1 cm and myometrium was 2.7 cm in thickness. The cut sur-

Received: March 20, 2002; accepted: May 12, 2002

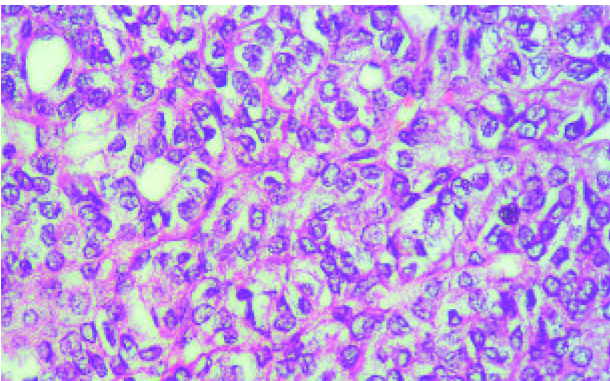
Correspondence: Fevziye KABUKCUOGLU, M.D., M. Ismail Hakki sk No: 10/1 Dogancilar, Uskudar, Istanbul 81160, Turkey; Fax: +90212 231 7537, E-mail: [etfaly@superonline.com](mailto:etfaly@superonline.com)

face of the left ovary had a cystic lesion 0.5 cm in diameter containing serous fluid.

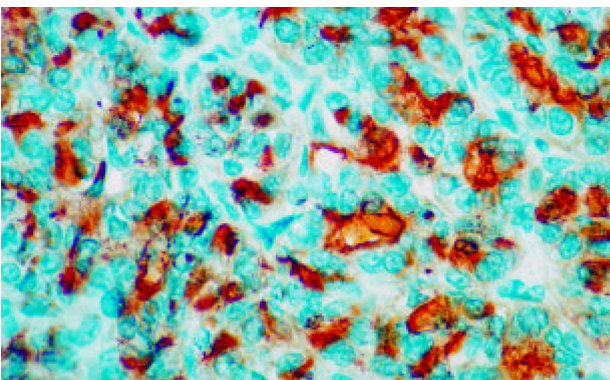
Histopathologic examination of the glossy parts of the right adnexial mass showed the characteristic appearance of nodular goiter with colloid filled follicles varying in size and intervening fibrous collagenous stroma (*Figure 1*).



**Figure 1.** Colloid-filled follicles varying in size with intervening fibrous stroma representing struma ovarii. Papillary carcinoma areas are noted adjacent to struma ovarii (HE x 125).



**Figure 2.** The tumor predominantly consists of follicles lined by overlapping ground glass nuclei with nuclear grooves. Papillary structures make up only a minor component of the lesion. (HE x 500).



**Figure 3.** Thyroglobulin reactivity of the tumor cells (x500)

There were foci of mononuclear inflammatory cells between the follicles. The grey-yellow areas described in the cut surface of the mass showed diffuse growth of malignant tumor, infiltrating mostly in follicular pattern. Papillary formations were also noted. The tumor cells had round to oval, overlapping nuclei with ground-glass appearance. Longitudinal grooves or inclusions could be detected in some of the nuclei (*Figure 2*). The cells showed a moderate degree of pleomorphism. In mitotically active areas, five to six atypical mitoses were counted in every 10 high-power fields. The tumor was restricted within the capsule and vascular invasion was not identified. Immunohistochemical study showed strong expression of thyroglobulin (Neomarkers, clone 4GB04+TGB05, prediluted) confirming the thyroid epithelial nature of the neoplasm (*Figure 3*). There was no staining for chromogranin (Neomarkers, clone LK2H10+PHE5, prediluted) and calcitonin (Neomarkers, prediluted). Based on these findings, the tumor was diagnosed as a follicular variant of papillary carcinoma arising in struma ovarii. The non-neoplastic ovary showed a follicular cyst. The pathologic examination of the hysterectomy material showed findings of chronic cervicitis, endometrium in the proliferative phase and follicular cysts in the left ovary. There was no tumor invasion over the surface of the right ovary. No tumor infiltration was encountered in the uterine serosa, fallopian tube and omentum. Atypical cells were not detected in the peritoneal fluid. The five para-aortic and pelvic lymph nodes were reactive.

Detailed examination of the thyroid gland was performed. She had grade I diffuse goiter, but she was devoid of symptoms of hyperthyroidism. Findings of ultrasonography and radioiodine scan of the thyroid were consistent with diffuse goiter. Thyroid function tests were within normal limits. T3: 1.51 ng/ml, T4: 7.5 ug/dl, sTSH: 0.492 uIU/ml, Anti TG: (-), Anti TPO: (-), free T4: 1.2 ng/dL, TRab: 5%. The possibility of a primary thyroid tumor was excluded. The patient was accepted as Stage Ia malignant struma ovarii and no other treatment was considered. Thyroid function tests and serum thyroglobulin checked at three-month intervals were within normal limits and the patient was disease-free in her two year follow-up clinically and radiologically.

### Discussion

Germ cell tumors constitute a very complicated group of tumors of the ovary and show labile characteristics of differentiation. Struma ovarii is a rare and highly specialized form of mature teratoma constituting 2% of all teratomas.<sup>12</sup> It is mandatory to determine the absence of a primary tumor in the thyroid to exclude an unusual metastasis of thyroid carcinoma to the ovary.<sup>4</sup> Struma ovarii may demonstrate all the pathologic patterns that may be found in the thyroid gland including malignancy.<sup>5,7,11,12</sup>

The diagnosis of malignant struma ovarii has been controversial because of absence of uniform diagnostic criteria, combined with the rarity of the tumor. Malignancy is represented by follicular carcinoma, papillary carcinoma or a mixed pattern, similar to the types of thyroid carcinoma.<sup>2,3,9,14</sup> These patterns may be confusing and differentiation of the follicular type from the granulosa cell tumor or the carcinoid may be difficult.<sup>11,16</sup> Immunohistochemical stains for thyroglobulin and chromogranin are necessary for differential diagnosis. According to some authors, malignancy can be diagnosed when the tumor shows definite invasion or metastases, while others diagnose malignancy on nuclear histologic findings.<sup>4,5,9</sup> The criteria for malignancy have been reviewed by Devaney et al and the presence of malignant nuclear features designated as ground-glass overlapping nuclei and nuclear grooves have been accepted as the most crucial criteria for papillary carcinoma.<sup>4</sup> Presence of vascular and capsular invasion support the diagnosis. Lesions showing hyperplastic type papillary formations, but lacking overlapping ground-glass nuclei have been diagnosed as proliferative struma ovarii.<sup>4</sup> Malignant behavior has not been observed in this category yet. Our case demonstrated no evidence of clinical malignancy or metastasis, however on the basis of nuclear features, cytological atypia and mitotic activity, the case was regarded as malignant struma ovarii.

Metastasis is uncommon in patients with malignant struma ovarii.<sup>9,15</sup> The most common sites are contralateral ovary, pelvic structures, bone, liver, brain and lungs.<sup>5,13</sup> The metastases can exhibit a follicular pattern and thus simulate peritoneal seeding of struma ovarii.<sup>6</sup> Nuclear atypia has been suggested to establish a lesion as a metastasis.<sup>3</sup> In any case, it is better to consider with caution benign appearing thyroid tissue arising in nonthyroidal sites. It is not always possible to estimate the behavior of struma ovarii. Even a purely benign-looking case may show malignant transformation after many years. Dardik described a case of struma ovarii with no evidence of malignant features, which recurred six years later with dissemination in the pelvis, retroperitoneum and liver and showed the features of papillary carcinoma.<sup>3</sup>

Because it is rarely encountered, the management of malignant struma ovarii has not been clearly defined yet. Some authors have advocated the management of malignant struma as other germ cell tumours.<sup>1</sup> Others have proposed that malignant struma should be treated like its thyroid counterpart.<sup>3,14</sup> Fertility sparing surgery is recommended for those who do not have high grade disease.<sup>14</sup> After completion of childbearing, treatment should be followed by total abdominal hysterectomy and bilateral salpingo-oophorectomy, lymph node dissection and omentectomy.<sup>3</sup> Functioning metastatic sites have been demonstrated by administration of radioiodine. Thyroidectomy and ablation with <sup>131</sup>I is necessary for advanced disease.<sup>13,15</sup> Iodine scans and thyroglobulin measurements are needed

for follow-up and detection of recurrence. Thyroglobulin production has been demonstrated in both benign and malignant struma ovarii. Raised serum and peritoneal fluid levels of thyroglobulin may be a useful marker of recurrence or metastasis.<sup>8,10</sup>

Malignant struma ovarii cases with no invasion or metastasis have a very good prognosis. Even disseminated cases have been reported to have a fairly good prognosis. Due to the relatively benign prognosis of the disease, we did not apply treatment other than radical surgery. However, the reported cases are few and prognosis may be difficult to estimate, so we believe that long-term follow-up as well as complete staging procedure is necessary to determine the course of the disease.

### References

1. Ayhan A, Yanyk F, Tuncer R, et al: Struma ovarii. *Int J Gynecol Obstet* 42:143-146, 1993.
2. Berghella V, Ngadiman S, Rosenberg H, et al: Malignant struma ovarii. A case report and review of the literature. *Gynecol Obstet Invest* 43:68-72; 1997.
3. Dardik RB, Dardik M, Westra W, Montz FJ: Malignant struma ovarii: Two case reports and a review of the literature. *Gynecol Oncol* 73:447-451, 1999.
4. Devaney K, Snyder R, Norris HJ, Tavassoli FA: Proliferative and histologically malignant struma ovarii: a clinicopathologic study of 54 cases. *Int J Gynecol Pathol* 12:333-343, 1993.
5. Gonzales A, Kaufman RH, Braungardt CD, et al: Adenocarcinoma of thyroid arising in struma ovarii (malignant struma ovarii). Report of two cases and review of the literature. *Obstet Gynecol* 21:567-576, 1963.
6. Karseladze AI, Kulinitch SI: Peritoneal strumosis. *Path Res Pract* 190:1082-1085, 1994.
7. Nogales FF: Germ cell tumours of the ovary. In: *Obstetrical and Gynecological Pathology*. (Eds: Fox H and Wells M); 4<sup>th</sup> ed, Churchill Livingstone, New York, 1995, pp 847-896.
8. O'Connell MEA, Fisher C, Harmer CL: Malignant struma ovarii: presentation and management. *Br J Radiol* 63:360-363, 1990.
9. Pardo-Mindan FJ, Vazquez JJ: Malignant struma ovarii. Light and electron microscopic study. *Cancer* 51:337-343, 1983.
10. Rose PG, Arafah B, Abdul-Karim FW: Malignant struma ovarii: recurrence and response to treatment monitored by thyroglobulin levels. *Gynecol Oncol* 70:425-427, 1998.
11. Szyfelbein WM, Young RH, Scully RE: Struma ovarii simulating ovarian tumors of other types. A report of 30 cases. *Am J Surg Pathol* 19(1): 21-29, 1995.
12. Talerma A: Germ cell tumors of the ovary. In: *Blaustein's Pathology of the Female Genital Tract*. (Ed: Kurman RJ), 4<sup>th</sup> ed, Springer-Verlag, New York 1994, pp 849-914.
13. Thomas RD, Batty VB: Metastatic malignant struma ovarii. Two case reports. *Clin Nucl Med* 17:577-578.
14. Vadmal MS, Smilari TE, Lovecchio JL, et al: Diagnosis and treatment of disseminated struma ovarii with malignant transformation. *Gynecol Oncol* 64:541-546, 1997.
15. Willemsse PHB, Oosterhuis JW, Aalders JG, et al: Malignant struma ovarii treated by ovariectomy, thyroidectomy, and <sup>131</sup>I administration. *Cancer* 60:178-182, 1987.
16. Woodruff JD, Rauh T, Markley RL: Ovarian struma. *Obstet Gynecol* 27:194-201, 1966.