

CASE REPORT

“Revertant” Mammary Solid Papillary Carcinoma in Lymph Node Metastasis

Gábor CSERNI

Bács-Kiskun County Teaching Hospital, Department of Surgical Pathology, Kecskemét, Hungary

A case of invasive carcinoma of mixed papillary and not otherwise specified ductal type with areas of solid papillary ductal carcinoma *in situ* (DCIS) is reported. The solid papillary areas were predominantly of low nuclear grade, but a small area of intermediate-grade solid papillary neoplasm was also seen within the tumor, together with an area suggestive of microinvasion. The massive regional nodal tumor load consisted of invasive papillary carcinoma and revertant low-grade solid papillary carcinoma with no myoepithelial cells around the circum-

scribed solid papillary areas. This is the first report of a solid papillary pattern simulating intraductal carcinoma in lymph nodes, and the first time that a solid papillary carcinoma is reported in association with invasive papillary carcinoma. The case suggests that mammary carcinomas with a solid papillary pattern may sometimes be of higher grade than usual, and do not always represent a DCIS, but may be invasive. (Pathology Oncology Research Vol 8, No 1, 74–77, 2002)

Keywords: ductal carcinoma in situ (DCIS), solid papillary carcinoma, breast cancer, revertant DCIS

Introduction

Breast carcinomas with a solid papillary pattern are rare. They are considered to be *in situ* carcinomas with neuroendocrine features, are often associated with mucinous carcinomas,^{12,20} and have a relatively favorable prognosis.

‘Revertant’ ductal carcinoma *in situ* (DCIS) is a name recently introduced to describe the occurrence of common DCIS patterns in lymph node metastases of breast carcinomas.² A ‘revertant’ DCIS simulates the real DCIS seen in the primary tumor, but this similarity in structure is superficial, because the revertant DCIS lacks a myoepithelial layer.

To the author’s knowledge, this is the first study to document ‘revertant’ low-grade solid papillary carcinoma in the lymph node metastasis of a breast cancer, its simultaneous occurrence with intermediate-grade solid papillary areas, microinvasion and invasive papillary carcinoma.

Materials and Methods

A 76-year-old woman was operated on for locally advanced breast carcinoma at another institution. The ulcerated tumor measured 4 cm in its largest dimension. A left-side mastectomy and axillary clearance were performed. The tumor was staged as pT4bpN2Mx (at least stage IIIB) disease. The patient refused to undergo any further diagnostic or therapeutic intervention.

The fixation of the specimens received was suboptimal. The tissues were further fixed in 7% buffered formalin and embedded in paraffin, and 4–5- μ m-thick sections were prepared from the blocks. These were stained with hemalaun and eosin. For the purpose of this study, immunohistochemistry was performed on multiple blocks, mainly on the solid papillary areas of the primary tumor and of the metastases. The antibodies used for the reactions are listed in *Table 1*.

Results

The primary tumor consisted of areas of invasive carcinoma of no special type (ductal carcinoma NST), had an invasive papillary component characterized by thin fibrovascu-

Received: Dec 21, 2001; *accepted:* Febr 25, 2002

Correspondence: Gábor CSERNI, MD, PhD; Bács-Kiskun County Teaching Hospital, Nyíri út 38., H-6000 Kecskemét, Hungary; Tel.: 36-76-481781 or 36-76-516700; Fax: 36-76-481219; E-mail: cserni@freemail.hu

lar cores covered by oriented nuclei with significant pleomorphism, and also contained areas of DCIS of the micropapillary, and solid papillary type (*Figure 1*). No mucinous area was identified within the invasive tumor, though intracytoplasmic vacuoles with diastase-resistant periodic acid Schiff-positive mucin (targetoid inclusions) were seen in some cells of the solid papillary tumor. On the basis of the two major components, the tumor was histologically classified as invasive carcinoma of mixed papillary type.¹⁴ The histological grade⁹ of the composite tumor was scored as follows: 2 for tubules, 3 for greatest pleomorphism, and 1 for mitoses, resulting overall in grade 2. The solid papillary area was predominantly of low nuclear grade, but an area with intermediate-grade nuclei was also encountered, and part of this area was suggestive of microinvasion (*Figure 2*). Low-grade cells, seen only in the solid papillary areas, were also identified in a few ducts as pagetoid spread of the *in situ* component.

The axillary content included 12 separate lymph nodes, 7 of which contained metastasis, and a conglomerate of multiple nodes measuring 3.5 cm in its largest dimension. Of the 7 metastatic nodes, 5 contained metastatic papillary carcinoma, whereas another lymph node and the conglomerate had large areas of metastatic deposits with a solid papillary pattern (*Figures 3 and 4*) together with smaller areas of invasive papillary carcinoma and NST ductal carcinoma.

Immunohistochemistry to smooth muscle actin (SMA) was positive in a fairly continuous circumferential pattern around the solid papillary tumor tested in the primary carcinoma, a staining consistent with a myoepithelial cell layer, and therefore the diagnosis of DCIS (*Figure 1*). In

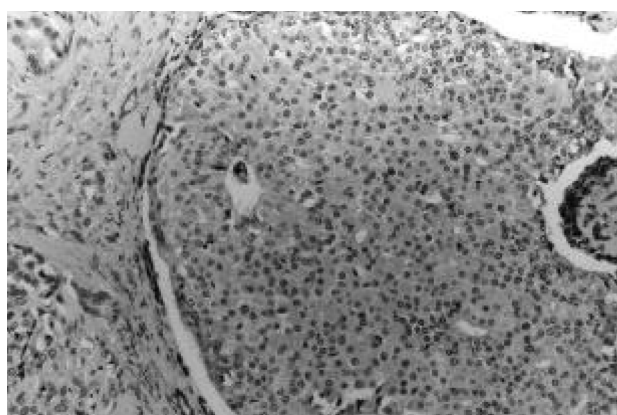


Figure 1. Solid papillary DCIS in association with invasive carcinoma. The myoepithelial layer is clearly identified despite the retraction artifact. Fibrovascular cores serve as internal control. (SMA with weak hematoxylin counterstaining, $\times 100$.)

Table 1. Details of the immunostains used

Antibody	Source (Catalogue number)	Dilution
SMA	DAKO, Glostrup, Denmark (N1584)	prediluted
Collagen IV	DAKO, Glostrup, Denmark (N1536)	prediluted
Chromogranin A	Biogenex, San Ramon, CA, USA (AM 126 5M)	prediluted
Synaptophysin	DAKO, Glostrup, Denmark (N1566)	prediluted
NSE	DAKO, Glostrup, Denmark (M873)	1:100
Her2/Neu	Novocastra Newcastle, UK (NCL-CB11)	1:40
ER	Novocastra, Newcastle, UK (NCL-ER-6F11)	1:60
PR	DAKO, Glostrup, Denmark (N1630)	1:2

SMA: Smooth muscle actin; NSE: neuron specific enolase; ER: estrogen receptor; PR: progesterone receptor.

the area suggestive of microinvasion, no myoepithelial cells were demonstrated by this reaction (*Figure 2*). On the other hand, the SMA reaction was negative on multiple sections around the solid papillary tumor in the lymph nodes, except for some cells, never giving a continuous perilesional rim; this pattern of staining was consistent with myofibroblasts around the tumor cell nests (*Figure 4*).

The solid papillary component of the tumor was negative with the Grimelius stain, chromogranin A and synaptophysin, and stained positively with the neuron-specific enolase antibody, as did the NST area. Different areas of the tumor tested were estrogen and progesterone receptor-positive, and her2/neu-negative.

Discussion

The pattern of DCIS is sometimes reproduced within (nodal) metastases of breast carcinoma. To the best of the author's knowledge, this phenomenon was first described by Lee et al,¹¹ who drew attention to invasive carcinoma with areas simulating micropapillary DCIS in both a primary tumor and its nodal metastasis.

The simulation of micropapillary DCIS in the cited case,¹¹ or of solid papillary DCIS in the present case, as a phenomenon, was called 'revertant' DCIS by Barsky et al., because of the partial recapitulation of the DCIS morphology in the metastatic invasive tumor.² 'Revertant' DCIS was described in 21% of a series of 200 metastatic carcinomas, especially in cases with a massive metastatic nodal load. It always exhibited a pattern concordant with the DCIS found in the primary tumor. The basic difference between the primary DCIS and the 'revertant' one was the lack of a myoepithelial layer in the latter.²

Despite some earlier case reports,^{5,16,18} solid papillary DCIS is a relatively recently recognized and rare type of DCIS.¹² Besides its structure, it is characterized by its common association with mucinous carcinoma, mucin production and neuroendocrine differentiation.¹² It is also referred to as neuroendocrine DCIS,²⁰ though the two synchronous descriptions of this entity in series of patients are contradic-

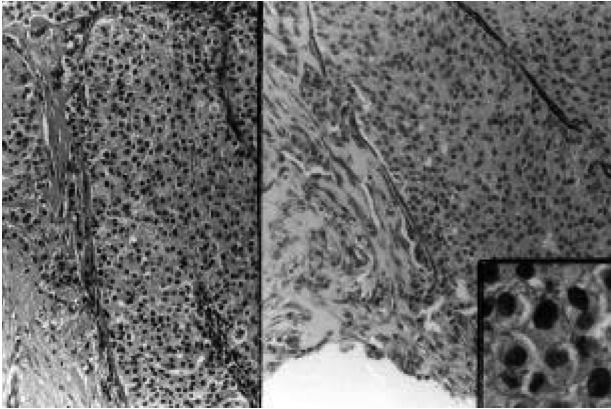


Figure 2. Edge of the intermediate-grade solid papillary DCIS with foci suggestive of microinvasion. The myoepithelium was disrupted at the bottom of the right section, where the tissues were artificially distorted. (Left: Hemalaun and eosin, x 100; SMA with weak hematoxylin counterstaining, x100.) Inset: Intermediate-grade nuclei (hemalaun and eosin, x 400.)

tory in some respects. In the series reported by Tsang and Chan,²⁰ all 34 tumors, either pure or associated with invasive carcinoma, had a definite myoepithelial layer demonstrated by immunohistochemistry to muscle-specific actin (HHF-35, Enzo Biochem, New York, USA), and all were positive for at least two neuroendocrine markers (chromogranin-A, synaptophysin or monoclonal neuron-specific enolase), estrogen and progesterone receptors, and negative for her2/neu and p53. In the 20 cases associated with invasive carcinoma, at least part of the invasive component was mucinous, corresponding to the type B colloid carcinoma described by Capella et al⁴ in a majority (80%) of the cases. No association with NST invasive ductal carcinoma was found in this series.²⁰ In contrast, many of the 20 tumors reported by Maluf and Koerner¹² failed to show a myoepithelial layer with SMA (Sigma Chemical Co, St Louis, Missouri, USA); 35% and 43% were not positive for neuroendocrine markers (Grimelius stain and chromogranin, respectively). Although the associated invasive carcinoma was of Capella type B mucinous⁴ or mucinous mixed in 11 of the 16 cases, the remaining 5 cases were associated with NST ductal carcinomas, 1 of which was poorly differentiated, while 3 were moderately differentiated, and 1 was unsuitable for grading.¹² The two series^{12,20} agree in the advanced age of the patients, the distinctive morphology of this tumor, the generally low nuclear grade, the frequent presence of intracellular and/or extracellular mucin in the intraductal component, the frequent association with mucinous carcinoma, the common neuroendocrine differentiation, the uniform estrogen receptor positivity and the predicted good prognosis.

Papillary neoplasms of the breast include benign and malignant lesions. Intraductal papillomas have been stated to pose a differential diagnostic problem in the recognition of solid papillary DCIS cases, especially if the latter have

spindle cells;^{12,13} papillomas were often associated with solid papillary DCIS in the series of Tsang and Chan²⁰. Malignant 'papillary' lesions include non-invasive neoplasms: intracystic papillary carcinoma, papillary DCIS and micropapillary DCIS;⁸ and invasive tumors: papillary and micropapillary carcinomas.¹⁵ As far as the author is aware, no association has been reported between these types of tumors despite their similar names, although they may coexist at times (e.g. micropapillary DCIS and invasive micropapillary carcinoma).

Solid papillary carcinoma is a further type of 'papillary' neoplasm in the breast. This name was challenged by Tsang and Chan because of the predominantly solid pattern, the lack of an evident association with papillary DCIS, and the non-committal term predisposing to overtreatment.²⁰ In our opinion, with regard to the delicate fibrovascular septa, the terms solid and papillary adequately describe this type of tumor, one probable case of which was described as resembling transitiocellular papilloma of the bladder.¹⁸ Although

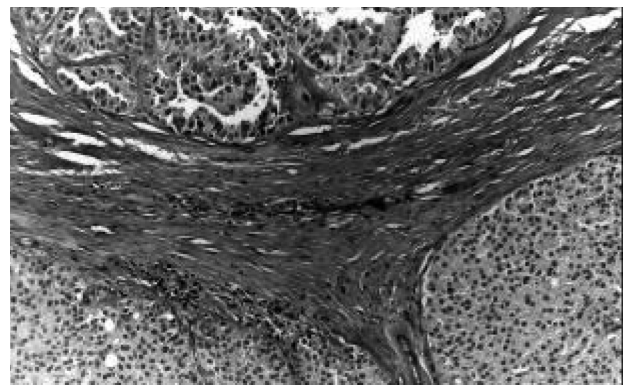


Figure 3. Metastasis with papillary and solid papillary patterns with high and low-grade nuclei, respectively. (Hemalaun and eosin, x 100.)

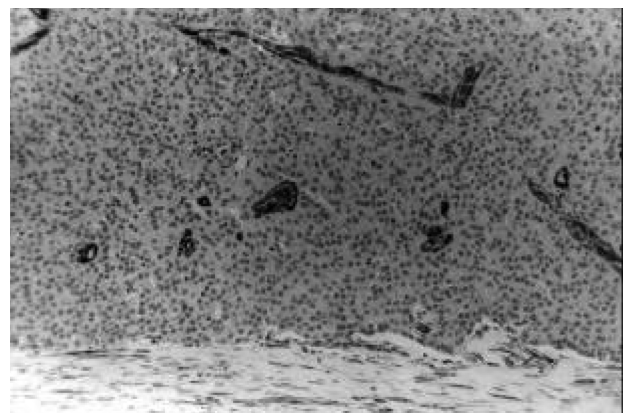


Figure 4. 'Revertant' solid papillary carcinoma of the lymph node. Note the lack of a myoepithelial layer. Fibrovascular cores serve as internal control. (SMA with weak hematoxylin counterstaining, x100.)

Maluf and Koerner claim that solid papillary carcinoma of the breast displays a “predominantly intraductal pattern of growth”, this type of tumor is generally viewed as a DCIS, despite the fact that myoepithelial cells could not always be demonstrated around the circumscribed solid papillary structures in the series of Maluf and Koerner.¹² It is our experience too, that some cases of solid papillary carcinoma have a SMA-positive rim around these structures, but some solid papillary areas may lack them. The absence of a myoepithelial layer favors the diagnosis of an invasive tumor. Likewise, the presence of a solid papillary tumor in lymph node metastases with no myoepithelial cells around it is indicative of ‘revertant DCIS’, no such example of which has been reported previously.

The fact that a myoepithelial layer could not always be demonstrated around the foci of mammary solid papillary carcinoma led Maluf and Koerner¹² to the restraint of describing this type of tumor as “predominantly *in situ*”. Although SMA is not specific for myoepithelial cells, and also labels myofibroblasts, its sensitivity is good,²¹ and the lack of an actin positive layer around a focus reminiscent of DCIS therefore argues in favor of the focus being invasive and simulating the DCIS pattern.^{2,11} In contrast with the generally low grade of such tumors, an area of intermediate-grade solid papillary DCIS was also seen in the tumor, and microinvasion was also suggested in this area. Despite the fact that solid papillary carcinomas are in general intraductal, microinvasion can be present in them, and the simulation of DCIS may occur in some examples of this neoplasm too. An example of this phenomenon is the ‘revertant’ solid papillary DCIS reported here. It has been suggested that there are practically no genetic differences between DCIS and the associated invasive carcinoma, and invasion is mainly an epigenetic phenomenon.^{1,2} A massive metastatic load could favor the reappearance of the DCIS pattern with no myoepithelial cell layer, a layer that is regarded by some authors as a natural tumor or invasion-suppressing barrier.^{1,19}

The relationship between the solid papillary carcinoma and the mixed papillary invasive carcinoma is not settled, and might involve a coincidence. Current research suggests that the grades of a DCIS and the associated invasive carcinoma are similar,^{6,7,10} which is consistent with the theory that a low-grade invasive tumor originates from a low-grade DCIS, and a high-grade invasive tumor from a high-grade DCIS.^{3,10,17} The progression of low-grade solid papillary DCIS into intermediate-grade solid papillary carcinoma or grade 2 invasive carcinoma of mixed papillary type with high-grade nuclei would contradict the previous theory and also the theory suggesting that solid papillary DCIS is a precursor of mucinous carcinoma with neuroendocrine features. However, our case fits in well with the series of Maluf and Koerner,¹² because solid papillary carcinoma in this example was associated with NST ductal cancer, and the solid papillary pattern was clearly not *in situ* in the nodal metastasis.

References

1. Barsky SH, Bose S: Should LCIS be regarded as a heterogeneous disease? *Breast J* 5:407-412, 1999.
2. Barsky SH, Doberneck SA, Sternlicht MD, et al: “Revertant” DCIS in human axillary breast carcinoma metastases. *J Pathol* 183:188-194, 1997.
3. Buerger H, Otterbach F, Simon R, et al: Different genetic pathways in the evolution of invasive breast cancer are associated with distinct morphological subtypes. *J Pathol* 189:521-526, 1999.
4. Capella C, Eusebi V, Mann B, et al: Endocrine differentiation in mucoid carcinoma of the breast. *Histopathology* 4:613-630, 1980.
5. Cross AS, Azzopardi JG, Krausz T, et al: A morphological and immunohistochemical study of a distinctive variant of ductal carcinoma *in situ* of the breast. *Histopathol* 9:1-37, 1985.
6. Diest PJ van: Ductal carcinoma *in situ* in breast carcinogenesis. *J Pathol* 187:383-384, 1999.
7. Douglas-Jones AG, Gupta SK, Attanoos RL, et al: A critical appraisal of six modern classifications of ductal carcinoma *in situ* of the breast (DCIS): correlation with grade of associated invasive carcinoma. *Histopathol* 29: 97-409, 1996.
8. Ellis IO, Elston CW, Poller DN: Ductal carcinoma *in situ*. In: Elston CW, Ellis IO (Eds) *The Breast, Systemic Pathology*, Volume 13, 3rd ed., pp 249-281. Churchill Livingstone, Edinburgh, 1998.
9. Elston CW, Ellis IO: Assessment of histological grade. In: Elston CW, Ellis IO (Eds) *The Breast, Systemic Pathology*, Volume 13, 3rd ed., pp 365-384. Churchill Livingstone, Edinburgh, 1998.
10. Lampejo OT, Barnes DM, Smith P, et al: Evaluation of infiltrating carcinomas with a DCIS component: correlation of the histologic type of the *in situ* component with the grade of the infiltrating component. *Semin Diagn Pathol* 11: 215-222, 1994
11. Lee AHS, Telfer TP, Millis RR: Metastatic breast carcinoma with appearance resembling micropapillary ductal carcinoma *in situ*. *J Clin Pathol* 48:380-382, 1995.
12. Maluf HM, Koerner FC: Solid papillary carcinoma of the breast. A form of intraductal carcinoma with endocrine differentiation frequently associated with mucinous carcinoma. *Am J Surg Pathol* 19:1237-1244, 1995.
13. Maluf HM, Zukerberg LR, Dickersin GR, et al: Spindle-cell argyrophilic mucin-producing carcinoma of the breast. Histological, ultrastructural, and immunohistochemical studies of two cases. *Am J Surg Pathol* 15:677-686, 1991.
14. National Coordinating Group for Breast Screening Pathology. Pathology reporting in breast cancer screening, 2nd ed., p65. NHS-BSP Publications, Sheffield, 1997.
15. Pinder SE, Elston CW, Ellis IO: Invasive carcinoma - usual histological types. In: Elston CW, Ellis IO (Eds) *The Breast, Systemic Pathology*, Volume 13, 3rd ed., pp 283-337. Churchill Livingstone, Edinburgh, 1998.
16. Rosen PP, Oberman HA: Tumors of the mammary gland. Fascicle 7, 3rd series, p217. AFIP, Washington DC, 1993.
17. Roylance R, Gorman P, Harris W et al: Comparative genomic hybridisation of breast tumors stratified by histological grade reveals new insights into the biological progression of breast cancer. *Cancer Res* 59:1433-1436, 1999.
18. Saphir O: Mucinous carcinoma of the breast. *Surg Gynecol Obstet* 72:908-914, 1941.
19. Sternlicht MD, Kedeshian P, Shao ZM, et al: The human myoepithelial cell is a natural tumor suppressor. *Clin Cancer Res* 3:1949-1958, 1997.
20. Tsang WYW, Chan JKC: Endocrine ductal carcinoma *in situ* (E-DCIS) of the breast. *Am J Surg Pathol* 20:921-943, 1996.
21. Yaziji H, Gown AM, Sneige N: Detection of stromal invasion in breast cancer: the myoepithelial markers. *Adv Anat Pathol* 7:100-109, 2000.