

## ARTICLE

# Immunohistochemical Expression of N-ras Oncogene is a Late Event in Head and Neck Carcinomas

John S. McDONALD<sup>1</sup>, Keith M. WILSON<sup>1</sup>, Peter GARTSIDE<sup>2</sup>, Robert L. SONKE<sup>1</sup>, Ljiljana PAVELIC<sup>1</sup>, Eric OKUM<sup>2</sup>, Julie NEANEN<sup>2</sup>, Jack L. GLUCKMAN<sup>1</sup>, Zlatko P. PAVELIC<sup>1</sup>

<sup>1</sup>Department of Otolaryngology-Head and Neck Surgery and <sup>2</sup>Department of Environmental Health, University of Cincinnati College of Medicine, Cincinnati, Ohio; <sup>3</sup>Medical School, Ohio State University, Columbus, Ohio

This study investigated the expression of the N-ras oncogene in routinely processed tissue sections from 133 patients with squamous cell carcinoma of the head and neck (SCCHN) by immunohistochemistry using anti-N-ras monoclonal antibody. N-ras expression was present in 67 of 133 (49.6%) cases. There was a highly significant correlation

between N-ras expression and clinical stage of disease ( $P=0.003$ ). This study confirmed that over-expression of the N-ras oncogene is common in SCCHN and that it may be an important event in the late stage of disease. (Pathology Oncology Research Vol 2, No1-2, 30-33, 1996)

**Key words:** head and neck cancer, immunohistochemistry, N-ras

## Introduction

It is well known that the staging of tumors using the TNM system is imperfect in predicting individual outcome and survival of patients with head and neck cancer. In an attempt to elucidate biological factors which may determine or help predict the aggressiveness of individual tumors, the experimental focus has turned to the aberrant expression of oncogenes and tumor suppressor genes as potential prognostic indicators.<sup>10,18,19,20</sup> Members of the *ras* oncogene family (H-ras, K-ras and N-ras) are among the most frequently altered oncogenes in pancreatic, colorectal, thyroid and lung cancers and myeloid leukemias.<sup>1,5</sup>

In a previous study, we analyzed the expression of H-ras, K-ras and N-ras oncogenes on frozen sections of 22 patients with primary squamous cell carcinoma of the head and neck (SCCHN) by immunohistochemistry using anti-ras monoclonal antibodies.<sup>15</sup> This study showed that immunohistochemically detectable *ras* protein was a relatively common event in SCCHN. It also demonstrated a trend toward an increase in *ras* expression with an increase in

tumor size and later stage of disease (stages 3 and 4) with no apparent correlation between *ras* protein expression and the presence or absence of regional lymph node involvement, site of occurrence, histopathologic differentiation, age, sex, or race.<sup>13</sup> The current retrospective study was undertaken to extend the findings of the previous study and to determine if there was truly a relationship between N-ras oncogene over-expression and late stage of disease.

## Materials and Methods

Archival tissue specimens from 133 patients treated surgically for SCCHN at the University of Cincinnati Medical Center and the Veterans Administration Hospital between 1980 and 1992 were evaluated for this study. All patients had only a single primary tumor and none had received prior treatment. Tissues fixed in 10% neutral buffered formaldehyde and processed for routine histopathologic evaluation were cut in 5 micron sections and the microwave heating technique originally described by Shi et al.<sup>26</sup> and modified by Pavelic et al.<sup>27</sup> was used for revealing previously unaccessible epitopes.

## Reagents

Mouse monoclonal antibody against N-ras protein (clone F155-277) was supplied by Oncogene Science, Inc. (Uniondale, NY), and the specificity was confirmed and reported by

Received: March 11, 1996; accepted: April 2, 1996

**Correspondence:** Zlatko P. PAVELIC, M.D., Ph.D., Professor and Director, Division of Molecular Oncology, Department of Otolaryngology-Head and Neck Surgery, College of Medicine, University of Cincinnati, Cincinnati, Ohio 45167-0528, USA. Tel (513) 558-6275; Fax (513) 558-5203.

Palejwala and Goldsmith.<sup>16,17</sup> The antibody was used at 1:10 dilution (final concentration 10 µg/ml). Negative controls were tissues incubated with the same dilution of mouse IgG<sub>1</sub>. Other reagents used were rabbit anti-mouse immunoglobulin (Dako Corp., Carpinteria, CA); peroxidase anti-peroxidase (PAP) complex (Dako Corp.) and normal human serum (Gibco BRL, Grand Island, NY).

#### Immunohistochemistry

Endogenous peroxidase activity in tissue samples was neutralized by 15 minute incubation in 3% H<sub>2</sub>O<sub>2</sub> in methanol. The slides were washed in phosphate buffered saline (PBS) and non-specific binding was blocked by applying normal rabbit serum in a humidity chamber at a dilution of 1:10 for 30 minutes. The slides were blotted and the primary anti-ras antibody in the appropriate optimized solution was applied for 2 hours at room temperature. The slides were then washed three times in PBS containing 3%, 2%, 1% normal human serum (NHS), respectively. The second antibody (rabbit anti-mouse immunoglobulin) diluted 1:25 with PBS containing 0.1% bovine serum albumin (BSA) and 1% NHS was applied for 1 hour at room temperature. Finally, PAP conjugate diluted 1:100 in PBS with 0.1% BSA was applied for 1 hour. The slides were then washed for 10 minutes in PBS, and diaminobenzidine tetrahydrochloride (DAB) was used as a chromogen. Prior to mounting, the slides were counter stained with hematoxylin.

#### Evaluation of slides

Tissue sections were evaluated randomly in a double blind fashion for the presence or absence of N-ras protein using light microscopy. A specimen was considered to be positive for the presence of the N-ras protein if greater than 1% of cells exceeded background levels of staining. Staining was graded according to intensity of cytoplasmic staining (i.e., light = 1, intermediate = 2, intense = 3) and the percent of cells stained (i.e., 1-33% = 1, 34 - 66% = 2, > 66% = 3). The values for each specimen were then totaled as 0,2,3,4,5,6 and grouped as 0 = 0; 1 = 2 and 3; 2 = 4,5 and 6.

#### Statistical methods

The number of patients with tumors, with N-ras expression, and stage were tabulated in contingency tables. Chi-square tests of significance were computed using the method of Peasson.

#### Results

The immunohistochemical expression of N-ras protein was evaluated on a total of 133 cases of primary SCCHN. N-ras expression was present in 67 of 133 (49.6%) cases. Table 1 shows a highly significant correlation between N-

ras expression and clinical stage of disease ( $p = 0.003$ ). Fig. 1 demonstrates that with progressing stage of disease there is a progressive increase in N-ras expression.

**Table 1. The number of tumors which did and did not demonstrate N-ras expression by stage of disease.**

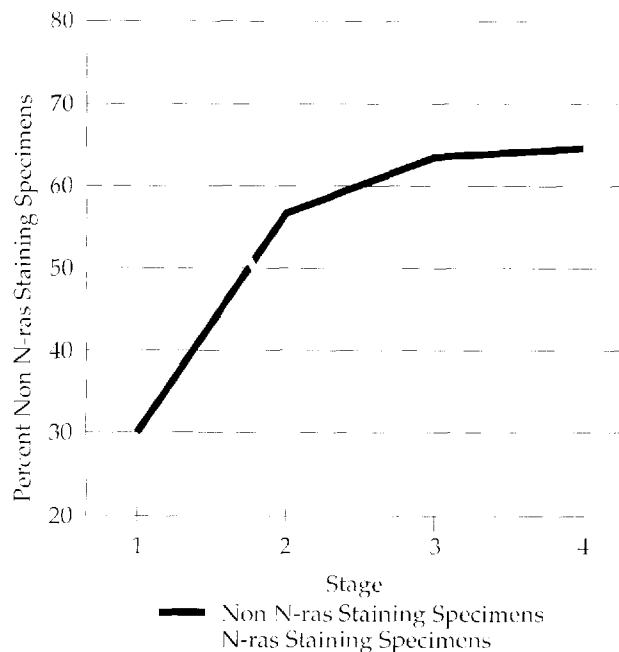
	Stage 1	Stage 2	Stage 3	Stage 4	Total
N-ras Absent	36	7	11	13	67
N-ras Present	15	9	18	24	66
Total	51	16	29	37	133

Chi-square (3 df) = 13.9; Significance:  $p = 0.003$

Fig. 2 shows that for Stage I SCCHN there was an inverse relationship between staining intensity and the percent of N-ras positive specimens. For Stage II SCCHN, no relationship between stage and stain was noted. For combined Stage III and Stage IV SCCHN's there was a clear relationship between an increase in the percent of N-ras positive specimens and intensity of staining.

#### Discussion

It has long been known that malignancy results from a progressive series or accumulation of genetic changes in a single clone of cells.<sup>22</sup> This change may be caused by mutagenesis (chemicals, radiation or viruses) or by retroviral transduction.<sup>11</sup> The role of the ras gene family in



**Figure 1.** There is a progressive increase in N-ras expression with progressing stage of disease (as shown by a decreasing percentage of non-N-ras staining specimens).

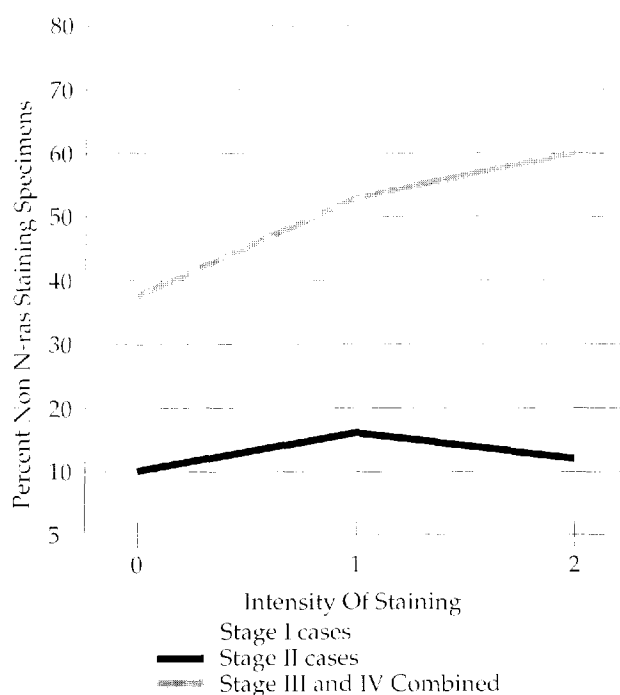


Figure 2. The relationship between N-ras expression as a function of staining with the clinical stage of disease.

different stages of carcinogenesis remains uncertain with somewhat conflicting data within the range of tumors studied.<sup>1,3,6,8,15,22,28</sup> Reports have also varied as to the relationship between *ras* expression and the stage of tumor development. Mitsudomi et al<sup>12</sup> studying *ras* mutations at codons 12, 13 and 61 in non-small cell lung cancers demonstrated an association between *ras* gene mutations and shortened survival, indicating that *ras* mutations may be an important event in the late stages of the development of lung cancer. This runs counter to the findings of Fearon and Vogelstein<sup>9</sup> in colorectal carcinoma in which *ras* mutations have been identified in the early stage of tumor development. Reports of the frequency of *ras* oncogene alteration in head and neck tumors in SCCHN are also somewhat contradictory. While reported to be a rare event in oral malignancies in the USA and Europe,<sup>7,12,23,25</sup> it has been reported to occur in 35% of oral cancers in India.<sup>21</sup>

Contrary to some of the preceding reports, this study and our earlier report of 22 patients<sup>13</sup> demonstrated that *ras* oncogenes over expression is a relatively common event in SCCHN and suggested that it may be an important event in the later stages of carcinogenesis.

## References

1. Agnantis NJ, Petraki C, Markoulatos P, and Spandidos DA: Immunohistochemical study of the *ras* oncogene expression in human breast lesions. *Anticancer Res* 6:1157-1160, 1986.
2. Armitage P and Doll R: The age distribution of cancer and a multi-stage theory of carcinogenesis. *Brit J Cancer* 8:1-12, 1954.
3. Balmain A, Ramsden M, Bowden GT, and Smith J: Activation of the mouse cellular Harvey-ras gene in chemically induced benign skin papillomas. *Nature* 307: 658-660, 1984.
4. Barbacid M: *Ras* genes. [Review] *Ann Review Biochem* 56:779-827, 1987.
5. Bos JL: *Ras* oncogenes in human cancer: a review. *Cancer Res* 49:4682-4689, 1989.
6. Candlish W, Kerr IB, and Simpson HW: Immunocytochemical demonstration and significance of *ras* p21 family oncogene product in benign and malignant breast disease. *J Pathol* 150:163-167, 1986.
7. Chang SE, Bhatia P, Johnson NW, Morgan PR, McCormick F, Young B, and Hiorns L: *Ras* mutations in United Kingdom examples of oral malignancies are infrequent. *Int J Cancer* 48:409-412, 1991.
8. DeBortoli ME, Abou-Issa H, Haley BE, and Cho-Chung YS: Amplified expression of p21 *ras* protein in hormone-dependent mammary carcinomas of humans and rodents. *Biochem Biophys Res Commun* 127:699-709, 1985.
9. Fearon ER, and Vogelstein B: A gene model for colorectal tumorigenesis. [Review] *Cell* 61:757-767, 1990.
10. Field JK: Oncogenes and tumor-suppressor genes in squamous cell carcinoma of the head and neck. [Review] *Oral Oncol Eur J Cancer* 28B: 67-76, 1992.
11. Field JK, and Spandidos DA: Expression of oncogenes in human tumours with special reference to the head and neck region. [Review] *J Oral Pathol* 16:97-107, 1987.
12. Hirano T, Steele PE, and Gluckman JL: Low incidence of point mutation at codon 12 of K-ras proto-oncogene in squamous cell carcinoma of the upper aerodigestive tract. *Ann Otol Rhinol Laryngol* 100:597-599, 1991.
13. McDonald JS, Jones H, Pavelic ZP, Pavelic LJ, Stambrook PJ, and Gluckman JL: Immunohistochemical detection of the H-ras, K-ras, and N-ras oncogenes in squamous cell carcinoma of the head and neck. *J Oral Pathol Med* 23: 342-346, 1994.
14. Mitsudomi T, Steinberg SM, Oie HK, Mulshine JL, Phelps R, Viallet J, Pass H, Minna JD, and Gazdar AF: *Ras* gene mutations in non-small cell lung cancers are associated with shortened survival irrespective of treatment intent. *Cancer Res* 51:4999-5002, 1991.
15. Ohuchi N, Thor A, Page DL, Horan Hand P, Halter SA, and Schlom J: Expression of the 21,000 molecular weight *ras* protein in a spectrum of benign and malignant human mammary tissues. *Cancer Res* 46: 2511-2519, 1986.
16. Palejwala S, and Goldsmith LT: Detection of Ki-ras proto-oncogene protein by a specific monoclonal antibody. *Biotechniques* 11:606-608, 1991.
17. Palejwala S, and Goldsmith LT: Ovarian expression of cellular Ki-ras p21 varies with physiological status. *Proc Natl Acad Sci USA* 89:4202-4206, 1992.
18. Pavelic ZP, Gluckman JL, Gapany M, Reising J, Craven JM, Kelley DJ, Pavelic LJ, Gapany S, Biddinger P, and Stambrook PJ: Improved immunohistochemical detection of p53 protein in paraffin embedded tissues reveals elevated levels in most head and neck and lung carcinomas: correlation with clinicopathological parameters. *Anticancer Res* 12:1389-1394, 1992.
19. Pavelic ZP, Pavelic LJ, Kuvellkar R, and Gapany S: High c-myc expression in benign colorectal lesions correlates with the degree of dysplasia. *Anticancer Res* 12:171-176, 1992.
20. Pavelic ZP, Pavelic LJ, Lower EE, Gapany M, Gapany S, Barker EA, and Preisler HD: c-myc, c-erbB2, and Ki-67

- expression in normal breast tissue, invasive and non-invasive breast carcinoma. *Cancer Res* 52:2597-2602, 1992.
21. Pavelic ZP, Portugal LG, Gootee MJ, Stambrook PJ, Smith C, Mugge RE, Pavelic LJ, Wilson K, Buncher RC, Li Y-Q, McDonald JS, and Gluckman JL: Retrieval of p53 protein in paraffin-embedded head and neck tumor tissues. *Arch Otolaryngol Head Neck Surg* 119:1206-1209, 1993.
  22. Quintanilla M, Brown K, Ramsden M, and Balmain A: Carcinogen-specific mutation and amplification of Ha-ras during mouse skin carcinogenesis. *Nature* 322:78-80, 1986.
  23. Rumsby G, Carter RI, and Gusterson BA: Low incidence of ras oncogene activation in human squamous cell carcinomas. *Br J Cancer* 61:365-368, 1990.
  24. Saranath D, Chang SE, Bhoite LT, Panchal RG, Kerr IB, Mehta AR, Johnson NW, and Deo MG: High frequency mutation in codons 12 and 61 of H-ras oncogene in chewing tobacco-related human oral carcinoma in India. *Br J Cancer* 63:573-578, 1991.
  25. Sheng ZM, Barrois M, Kljjanienko J, Micheau C, Richard JM, and Riou G: Analysis of the c-Ha-ras-1 gene for deletion, mutation, amplification and expression in lymph node metastases of human head and neck carcinomas. *Br J Cancer* 62:398-404, 1990.
  26. Shi SR, Key ME, and Kalra KL: Antigen retrieval in formalin-fixed, paraffin-embedded tissues: an enhancement method for immunohistochemical staining based on microwave oven heating of tissue sections. *J Histochem Cytochem* 39:741-748, 1991.
  27. Solomon E, Borrow J and Goddard AD: Chromosome aberrations and cancer. [Review] *Sci* 254:1153-1160, 1991.
  28. Whittaker JL, Walker RA, and Varley JM: Differential expression of cellular oncogenes in benign and malignant human breast tissue. *Int J Cancer* 38:651-655, 1986.

## **BIO-RAD Laboratories**

is your reliable partner  
in Hungary

in chromatography, electrophoresis, blotting methods,  
DNA techniques, densitometers, confocal systems

Address: 1126 Bösztörményi u. 13-15. tel/fax: 155-9641