

## ARTICLE

## Differential Expression of Runx2 and Indian Hedgehog in Cartilaginous Tumors

Hye-Rim PARK,<sup>1</sup> Yong-Koo PARK<sup>2</sup>

<sup>1</sup>Department of Pathology, Hallym University, Anyang, <sup>2</sup>Department of Pathology, Kyung Hee University, Seoul, Korea

Runx2-Cbfa1, a Runt transcription factor, plays important roles during skeletal development. In its absence, chondrocyte hypertrophy is severely impaired and there is no vascularization of cartilage templates during skeletal development. In addition, Indian hedgehog (Ihh) signaling molecules control the space and timing of chondrocyte differentiation. Our goal was to gain a better understanding of the molecular process underlying the development of chondrosarcoma and to investigate whether there is a biological difference among variable types of chondrosarcomas. To accomplish this we collected a series of 10 enchondromas and 57 chondrosarcomas (conventional, n = 17; mesenchymal, n = 20; clear cell, n = 20), and investigated the expression of Runx2 and Ihh in these cartilaginous tumors by immunohistochemistry. Cellular and matrix-rich areas were evaluated separately. Runx2 was expressed in 100% of conventional, mesenchy-

mal, and clear cell chondrosarcomas, and in 30% of enchondromas. Higher levels of expression of Runx2 were found in cellular areas than in matrix-rich areas. Expression levels increased with increasing histological grade in conventional chondrosarcoma, suggesting involvement in tumor progression. Ihh was expressed in 100% of conventional and clear cell chondrosarcomas, especially in matrix-rich areas. Mesenchymal chondrosarcomas revealed only focal expression of Ihh in matrix-rich areas. Small cell areas were negative. Ihh was absent or focally expressed in enchondromas. These findings demonstrate that Runx2 expression is active in variable chondrosarcomas compared to enchondromas, suggesting its importance in growth and differentiation of neoplastic cartilage. Ihh expression is considered a marker of the hypertrophic stage of differentiation in these tumor cells. (Pathology Oncology Research Vol 13, No 1, 32–37)

*Key words:* Runx2, Indian hedgehog, cartilaginous tumors

### Introduction

Chondrosarcoma is a malignant cartilage-forming tumor of bone, with distinct clinicopathological subtypes. Chondrocyte proliferation and differentiation occur in an organized manner and result in the formation of a growth plate composed of layers of chondrocytes at different stages of differentiation including resting, proliferating,

prehypertrophic, hypertrophic, and terminal hypertrophic chondrocytes. In cartilaginous tumors, there is a range of differentiation in comparison to the normal growth plate. Enchondroma and conventional chondrosarcomas resemble proliferating chondrocytes. Primitive cells in mesenchymal chondrosarcoma resemble resting chondrocytes in the growth plate, whereas clear cell chondrosarcoma recapitulates hypertrophic cells.<sup>1</sup>

Runx2 (runt-related transcription factor 2) is a Runx family transcription factor that acquires DNA binding activity by heterodimerizing with Cbfb.<sup>2</sup> Runx2-Cbfa1 plays important roles during skeletal development. Runx2<sup>-/-</sup> mice die just after birth and completely lack bone formation because of the absence of osteoblast differentiation, demonstrating that Runx2 is essential for osteoblast differentiation.<sup>3</sup> In the absence of Runx2, chondrocyte hypertrophy is severely impaired and there is no vascularization

*Received:* August 30, 2006; *accepted:* Jan 15, 2007

*Correspondence:* Yong-Koo PARK, Department of Pathology, Kyung Hee University Hospital, #1 Hoeki-dong, Dongdaemun-ku, Seoul 130-702, Korea, Tel: + 82-2-958-8742, fax: + 82-2-957-0489, E-mail: ykpark@khmc.or.kr

This work was supported by the Korea Science and Engineering Foundation (KOSEF) grant funded by the Korea government (MOST) (No. R13-2002-020-01001-0).

of cartilage templates during skeletal development. These tissue-specific functions of Runx2 are likely to be dependent on its interaction with other proteins.<sup>4</sup>

For example, Runx2 promotes chondrocyte maturation; chondrocyte maturation is delayed in Runx2<sup>-/-</sup> mice, but overexpression of Runx2 in chondrocytes restores maturation.<sup>5</sup> Runx2<sup>-/-</sup>3<sup>-/-</sup> mice, which completely lack Ihh expression, have severely shortened limbs because of reduced and disorganized chondrocyte proliferation and reduced cell size in the diaphyses. Further, the introduction of Runx2 to Runx2<sup>-/-</sup> chondrocytes induces Ihh expression, and Runx2 directly regulates the Ihh promoter. The above findings indicate that Runx2 is also involved in chondrocyte proliferation and that Runx2 coordinates chondrocyte maturation and proliferation by regulating Ihh expression.<sup>6</sup> Several lines of evidence suggest that Ihh in the prehypertrophic chondrocytes is a target of Runx2 in growth plates.<sup>5,7,8</sup> Yoshida et al<sup>6</sup> demonstrated that chondrocyte maturation is dependent on the dosages of Runx2 and Runx3 and that the absence of both causes a complete lack of chondrocyte maturation. They further showed that Runx2 enhances chondrocyte proliferation through the direct induction of Ihh expression.<sup>6,9</sup> However, most studies of Ihh focus on its expression in the growth plate and its effect on cultured chondrocytes, while little is known about its role in chondrosarcoma development.

Ihh plays important roles in the formation of the growth plate. The limbs of Ihh<sup>-/-</sup> mice are severely diminished because of reduced chondrocyte proliferation, indicating that Ihh promotes chondrocyte proliferation;<sup>7</sup> thus, Ihh regulates both the maturation and proliferation of chondrocytes. Within the normal growth plate, the Ihh/parathyroid hormone-related protein (PTHrP) negative feedback loop plays an important role in the regulation of chondrocyte growth and differentiation.<sup>10</sup>

We investigated molecules involved in chondrocyte proliferation and differentiation by comparing the protein expression of Runx2 and Ihh between different subsets of cartilaginous tumors. We discussed their parallel relationships to normal cartilage growth and differentiation according to the distinct histological chondrosarcoma subtypes.

## Materials and methods

### Pathological material

Formalin-fixed, paraffin-embedded material was used from 10 enchondromas and 57 chondrosarcomas. Cases were collected from the surgical pathology files of the Kyung Hee University Hospital, Hallym University Sacred Heart Hospital, and Mayo Clinic. The protocol was reviewed and approved by the Institutional Review Board at Kyung Hee University Hospital. All cases were independently reviewed by two authors (HRP, YKP), and the diagnoses were confirmed in all instances. Histological grading was performed according to Evans et al.<sup>11</sup>

### Immunohistochemistry

The avidin-biotin complex (ABC) method was performed on 4- $\mu$ m-thick tissue sections using the Envision ChemMate kit (DAKO Corporation, Carpinteria, CA) and goat ImmunoCruz staining system (Santa Cruz Biotechnology Inc., Santa Cruz, CA). Sections were deparaffinized with xylene for 15 min and treated in a microwave oven using 0.01 mol/l citrate buffer (pH 6.0) for 30 min for Runx2. Sections for Ihh were treated with Protease (Ventana Medical System, Tucson, AZ) for 4 min. Pretreated sections were incubated with the rabbit polyclonal antibody M-70 directed against Runx2 (PEBP2 $\alpha$ A; 1:25, Santa Cruz) and goat polyclonal antibody C-15 against Ihh (1:100, Santa Cruz). Positive tissue controls included osteosarcoma for Runx2 and fetal growth plate for Ihh, which showed specific binding of the antibody. Negative procedural controls were also confirmed by using non-immune serum in place of primary antibody.

### Evaluation and scoring

Two observers (HRP, YKP) evaluated the slides independently. Scoring was performed according to staining intensities and the percentage of positive cells. Cellular and matrix-rich areas were evaluated separately. Each zone was scored from 0 (no expression), 1+ (1-24% positive), 2+ (25-49% positive), to 3+ (50-100% strong expression).

## Results

### Clinicopathologic data

Chondrosarcoma cases included 17 conventional, 20 mesenchymal and 20 clear cell chondrosarcomas. Among 10 enchondromas, 8 cases were of phalangeal origin and 2 were non-phalangeal. All the conventional chondrosarcomas were of central location and non-phalangeal. Conventional chondrosarcomas were assigned histologic grades as follows: 9 were grade I, 5 grade II, and 3 grade III.

### Runx2 expression

Three of 10 enchondromas focally expressed Runx2 (Table 1, Figs. 1a and b). In contrast, Runx2 was expressed in 100% of conventional, mesenchymal, and clear cell chondrosarcomas (Fig. 1e). Higher levels of expression were found in cellular areas than in matrix-rich areas. Expression levels increased with increasing histological grade in conventional chondrosarcoma (Table 1, Figs. 1c and d). In mesenchymal chondrosarcomas, expression of Runx2 was mainly noted in small cell areas

**Table 1. Expression of Runx2 and Ihh in cartilaginous tumors**

IHC	Enchondroma	Conventional chondrosarcoma			Mesenchymal chondrosarcoma	Clear cell chondrosarcoma
		grade I	grade II	grade III		
Runx2						
0	7 (70%)	0	0	0	0	0
1+	3 (30%)	9 (100%)	1 (20%)	0	0	0
2+	0	0	4 (80%)	0	4 (20%)	17 (85%)
3+	0	0	0	3 (100%)	16 (80%)	3 (15%)
Ihh						
0	8 (80%)	0	0	0	12 (60%)	0
1+	2 (20%)	9 (100%)	2 (40%)	2 (67%)	8 (40%)	0
2+	0	0	3 (60%)	1 (33%)	0	10 (50%)
3+	0	0	0	0	0	10 (50%)
Total	10 (100%)	9 (100%)	5 (100%)	3 (100%)	20 (100%)	20 (100%)

IHC: immunohistochemistry

(Fig. 1f). The immunohistochemical localization of Runx2 was both nuclear and cytoplasmic. Normal growth plate exhibited focal immunoreactivity for Runx2 protein, especially in primary spongiosa.

#### *Ihh expression*

Ihh was not expressed or focally expressed in enchondromas (Table 1, Figs. 2a and b). In contrast, Ihh was expressed in 100% of conventional and clear cell chondrosarcomas, especially in matrix-rich areas. Expression of Ihh was not correlated with the histological grade of conventional chondrosarcomas (Table 1, Figs. 2c and d). In clear cell chondrosarcomas, expression of Ihh was diffusely noted in the cytoplasm of clear round tumor cells (Fig. 2e). Mesenchymal chondrosarcomas revealed only focal expression of Ihh in matrix-rich areas. Small cell areas were negative (Fig. 2f). Ihh displayed mainly cytoplasmic immunolocalization. Normal growth plate and endochondral ossification area exhibited positive reaction mainly in the hypertrophic zone. The expression pattern of Ihh was not correlated with that of Runx2 in the variable types of chondrosarcomas.

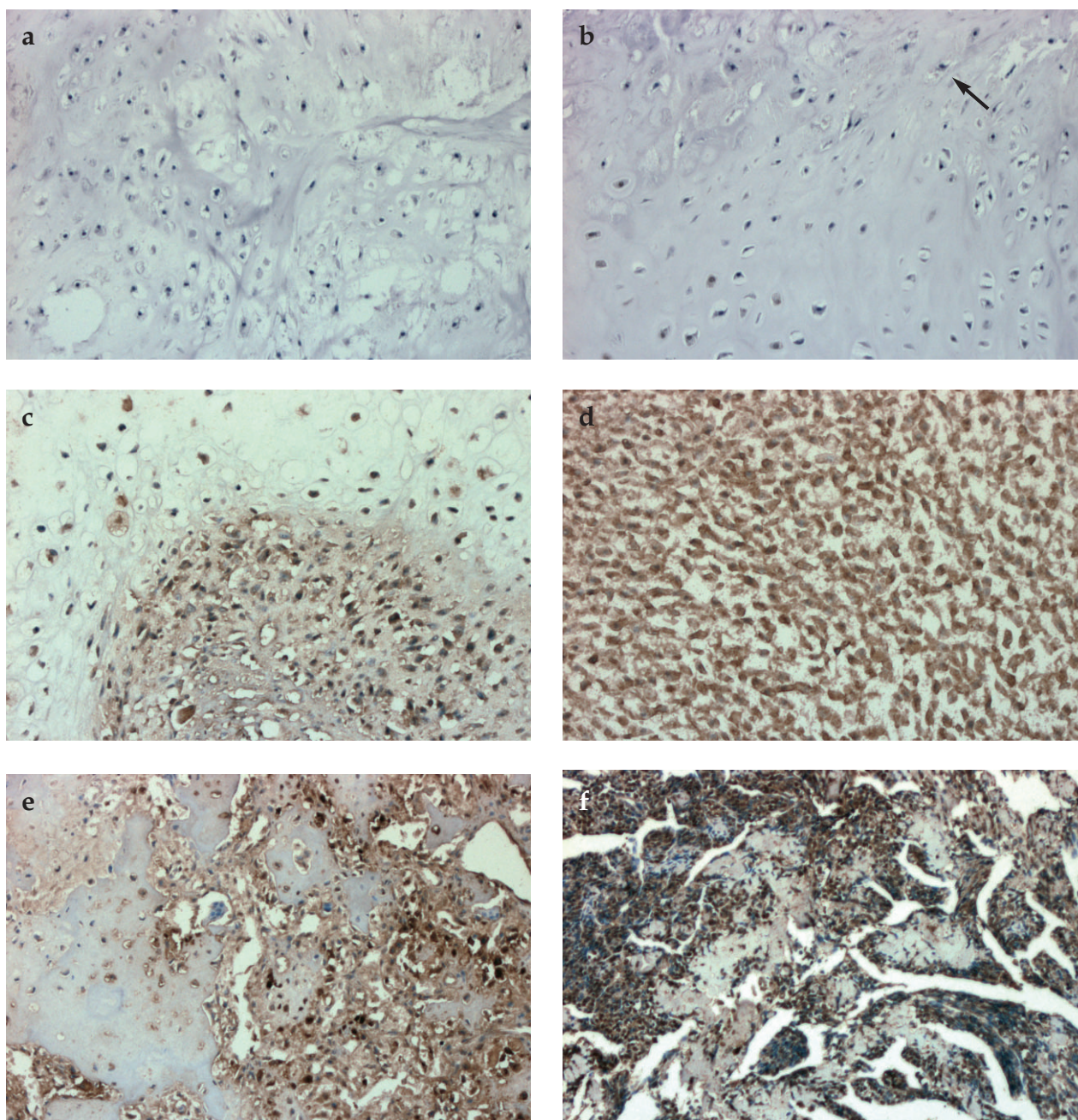
#### **Discussion**

In the present study, Runx2 was expressed in all examined samples of conventional, mesenchymal and clear cell chondrosarcomas. In contrast, 30% of enchondroma samples were focally positive for Runx2 expression. Higher levels of expression were found in cellular areas than in matrix-rich areas, as in the proliferating/pre-hypertrophic growth plate zone in comparison with the hypertrophic/calcifying zone. Thus, in chondrosarcoma, Runx2 signaling is active and seems to increase with histological grade,

in parallel with the increased proliferative activity. Papachristou et al<sup>12</sup> also reported positive staining for the Runx2 transcription factor in 38% and 97.8% of enchondromas and chondrosarcomas, respectively. In their series, 7 cases (33.3%) of enchondromas were also 1+ immunoreactive.

Runx2 is expressed in preosteoblasts, osteoblasts, prechondrocytes and prehypertrophic chondrocytes. Its biological functions in chondrocytes and osteoblasts are clearly distinct, but the basis for this tissue specificity is unknown. At the molecular level, tissue specificity of Runx2 function is likely to be dependent on its interaction with other transcription complex partners.<sup>4</sup> Our analyses suggest the active role of cartilage signaling molecules in chondrosarcoma. For Runx2 proteins, there was a trend towards more extensive and intense expression in the cellular areas in comparison with the matrix-rich areas. The cellular areas are also the areas in which higher numbers of mitoses are found; thus, they are more active in terms of proliferation. From this perspective, the expression of Runx2 within the cellular areas reflects the prevalent expression in the proliferative zone, similar to the other growth-regulating molecules.<sup>13</sup>

Previously published data on the role of Runx2 in chondrocyte differentiation suggest that it is involved in regulating Ihh signaling.<sup>5</sup> Ihh is a major regulator of bone development and growth. It coordinates chondrocyte proliferation, chondrocyte differentiation and osteoblast differentiation.<sup>14</sup> The skeletal phenotype of *Ihh*<sup>(-/-)</sup> embryos represents the sum of disturbances in three separate cell populations, the chondrocytes, the osteoblasts and the vasculature, each of which is a direct target of hedgehog signaling. Ihh has been shown not only to cause increased expression of PTHrP but also to stimulate cellular proliferation by an independent mechanism.<sup>15,16</sup>

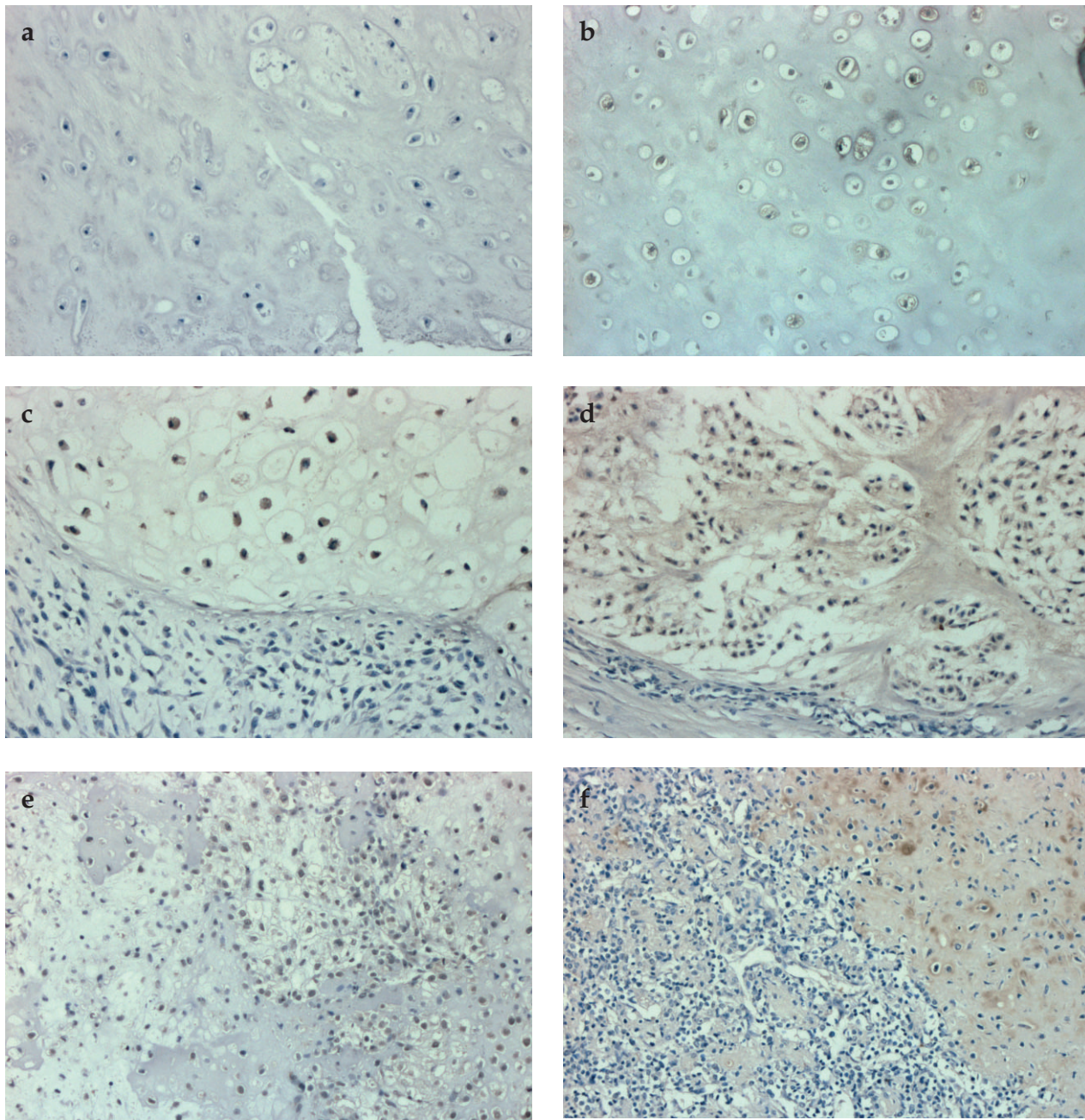


**Figure 1.** Runx2 expression in variable cartilaginous tumors. (a) Enchondroma negative for Runx2 (x100). (b) Enchondromas with focal, weak expression of Runx2 (arrow) (x100). (c) Grade II conventional chondrosarcoma expressing Runx2, especially in cellular areas (x100). (d) Grade III conventional chondrosarcoma with diffuse strong expression of Runx2 (x100). (e) Clear cell chondrosarcoma with diffuse Runx2 expression (x100). (f) In mesenchymal chondrosarcoma, expression of Runx2 was noted in small cell areas (x40).

Kindblom et al<sup>15</sup> showed that Ihh and PTHrP were expressed mainly in early hypertrophic chondrocytes in the human growth plate.

Thus, here our focus was the expression of Ihh in benign and malignant chondroid neoplasms for comparison with Runx2 expression. In our study, Ihh was not expressed or focally expressed in enchondromas. In contrast, Ihh was

expressed in 100% of conventional and clear cell chondrosarcomas, especially in matrix-rich areas. Clear cell chondrosarcomas revealed diffuse expression of Ihh in clear tumor cells. Mesenchymal chondrosarcomas revealed only focal expression of Ihh in matrix-rich areas. Small cell areas were negative. The expression of Runx2 and Ihh was not correlated in chondrosarcomas. Recently,



**Figure 2.** *Ihh* expression in variable cartilaginous tumors. (a) Enchondroma negative for *Ihh* (x100). (b) Enchondroma with focal expression of *Ihh* (arrow) (x100). (c,d) Conventional chondrosarcoma with moderate expression of *Ihh*, especially in matrix-rich areas (x100). (e) Diffuse *Ihh* expression in the tumor cells in clear cell chondrosarcoma (x100). (f) In mesenchymal cell chondrosarcomas, small cell areas were negative for *Ihh* (x100).

two interesting literatures were reported about the role of *Ihh* in chondroid neoplasms. Rozeman et al<sup>17</sup> showed that *Ihh* signaling is absent in enchondromas and central chondrosarcomas with quantitative real-time polymerase chain reaction (PCR). However, Tiet et al<sup>18</sup> reported that *Ihh* was expressed in all solitary enchondromas and all chondrosarcoma specimens using reverse transcriptase (RT)-PCR

analysis, although the levels were variable. Even among the chondrosarcomas, there was no correlation between higher tumor grade and increasing gene expression level, explaining some of the clinical heterogeneity associated with cartilage neoplasia.

Histological comparison of the cartilaginous cells of the growth plate in their different states of differentiation and

the distinct histological chondrosarcoma subtypes shows striking similarities.<sup>1,19</sup> Conventional chondrosarcomas are neoplasms of differentiated neoplastic chondrocytes, which can undergo multiphenotypic modulations. Mesenchymal chondrosarcomas represent the paradigmatic tumor entity of neoplastic chondroneogenesis, which shows all steps of cell differentiation stages starting from cells that have barely differentiated into mesenchyme.<sup>19</sup> Clear cell chondrosarcoma is a low-grade tumor characterized by tumor cells with clear, empty cytoplasm. These tumor cells are similar to hypertrophic cells of the growth plate, as confirmed by the expression of collagen type X and osteonectin.<sup>19</sup> In this context, we could interpret the expression pattern of Runx2 and Ihh in various cartilaginous tumors. Runx2 was mainly expressed in cellular proliferative areas, especially in conventional high-grade and mesenchymal chondrosarcomas. Ihh was mainly expressed in clear cell chondrosarcoma, similar to hypertrophic cells. Ihh expression was absent in small cell areas of mesenchymal chondrosarcoma. Thus, the overall expression pattern of Runx2 and Ihh in chondrosarcomas reflects different stages of differentiation according to the specific tumor subtypes.

In summary, to investigate the role of cartilage signaling molecules in tumorigenesis, we compared the expression of Runx2 and Ihh in variable cartilaginous tumors. We demonstrated that Runx2 expression was active in variable chondrosarcomas compared to enchondromas, suggesting its importance in growth and differentiation of neoplastic cartilage. Ihh expression was mainly localized to the tumor cells that exhibited characteristics of the hypertrophic stage of differentiation rather than the common features of neoplastic cells. We suggest that this outcome reflects differential expression of Runx2 and Ihh based on differentiation stage and tumor subtype.

## References

1. Bovee JVMG, Cleton-Jansen AM, Taminiau AHM, Hogendoorn PCW: Emerging pathways in the development of chondrosarcoma of bone and implications for targeted treatment. *Lancet Oncol* 6: 599-607, 2005
2. Kundu M, Javed A, Jeon JP, Horner A, Shum L, Eckhaus M, Muenk M, Lian JB, Yang Y, Nuckolls GH, Stein GS, Liu PP: Cbfb $\beta$  interacts with Runx2 and has a critical role in bone development. *Nat Genet* 32: 639-644, 2002
3. Komori T, Yagi H, Nomura S, Yamaguchi A, Sasaki K, Deguchi K, Shimizu Y, Bronson RT, Gao Y, Inada M, Sato M, Okamoto R, Kitamura Y, Yoshiki S, Kishimoto T: Targeted disruption of Cbfa1 results in a complete lack of bone formation owing to maturational arrest of osteoblasts. *Cell* 89: 755-764, 1997
4. Wang WF, Wang YG, Reginato AM, Glotzer DJ, Fukai N, Plotkina S, Karsenty G, Olsen BR: Groucho homologue Grg5 interacts with the transcription factor Runx2-Cbfa1 and modulates its activity during postnatal growth in mice. *Dev Biol* 270: 364-381, 2004
5. Takeda S, Bonnamy JP, Owen MJ, Ducy P, Karsenty G: Continuous expression of Cbfa1 in nonhypertrophic chondrocytes uncovers its ability to induce hypertrophic chondrocyte differentiation and partially rescues Cbfa1-deficient mice. *Genes Dev* 15: 467-481, 2001
6. Yoshida CA, Yamamoto H, Fujita T, Furuichi T, Ito K, Inoue KI, Yamana K, Zanma A, Takada K, Ito Y, Komori T: Runx2 and Runx3 are essential for chondrocyte maturation, and Runx2 regulates limb growth through induction of Indian hedgehog. *Genes Dev* 18: 952-963, 2004
7. St-Jacques B, Hammerschmidt M, McMahon AP: Indian hedgehog signaling regulates proliferation and differentiation of chondrocytes and is essential for bone formation. *Genes Dev* 13: 2072-2086, 1999
8. Kim IS, Otto F, Zabel B, Mundlos S: Regulation of chondrocyte differentiation by Cbfa1. *Mech Dev* 80: 159-170, 1999
9. Komori T: Regulation of skeletal development by the Runx family of transcription factors. *J Cell Biochem* 95: 445-453, 2005
10. Alexandre C, Jacinto A, Ingham PW: Transcriptional activation of hedgehog target genes in *Drosophila* is mediated directly by the cubitus interruptus protein, a member of the GLI family of zinc finger DNA-binding proteins. *Genes Dev* 10: 2003-2013, 1996
11. Evans HL, Ayala AG, Romsdahl MM: Prognostic factors in chondrosarcoma of bone. A clinicopathologic analysis with emphasis on histologic grading. *Cancer* 40: 818-831, 1977
12. Papachristou DJ, Papachristou GJ, Papaefthimiou OA, Agnantis NJ, Basdra EK, Papavassiliou AG: The MAPK-AP-1/Runx2 signalling axes are implicated in chondrosarcoma pathobiology either independently or via up-regulation of VEGF. *Histopathology* 47: 565-574, 2005
13. Romeo S, Bovee JVMG, Jadnanansing NAA, Taminiau AHM, Hogendoorn PCW: Expression of cartilage growth plate signaling molecules in chondroblastoma. *J Pathol* 202: 113-120, 2004
14. Kronenberg HM: Developmental regulation of the growth plate. *Nature* 423: 332-336, 2003
15. Kindblom JM, Nilsson O, Hurme T, Ohlsson C, Savendahl L: Expression and localization of Indian hedgehog (Ihh) and parathyroid hormone related protein (PTHrP) in the human growth plate during pubertal development. *J Endocrinol* 174: R1-6, 2002
16. Karp SJ, Schipani E, St Jacques B, Hunzelman J, Kronenberg H, McMahon AP: Indian hedgehog coordinates endochondral bone growth and morphogenesis via parathyroid hormone related-protein-dependent and -independent pathways. *Development* 127: 543-548, 2000
17. Rozeman LB, Hameetman L, Cleton-Jansen AM, Taminiau AHM, Hogendoorn PCW, Bovee JVMG: Absence of IHH and retention of PTHrP signalling in enchondromas and central chondrosarcomas. *J Pathol* 205: 476-482, 2005
18. Tiet TD, Hopyan S, Nadesan P, Gokgoz N, Poon R, Lin AC, Yan T, Andrulis IL, Alman BA, Wunder JS: Constitutive hedgehog signaling in chondrosarcoma up-regulates tumor cell proliferation. *Am J Pathol* 168: 321-330, 2006
19. Aigner T: Towards a new understanding and classification of chondrogenic neoplasias of the skeleton – biochemistry and cell biology of chondrosarcoma and its variants. *Virchows Arch* 441: 219-230, 2002